

1-1-1955

# Clinical and pathologic studies of a dermatitis of immature Iowa swine.

Lloyd Diehl Jones  
*Iowa State College*

Follow this and additional works at: <https://lib.dr.iastate.edu/rtd>

## Recommended Citation

Jones, Lloyd Diehl, "Clinical and pathologic studies of a dermatitis of immature Iowa swine." (1955). *Retrospective Theses and Dissertations*. 18436.  
<https://lib.dr.iastate.edu/rtd/18436>

This Thesis is brought to you for free and open access by the Iowa State University Capstones, Theses and Dissertations at Iowa State University Digital Repository. It has been accepted for inclusion in Retrospective Theses and Dissertations by an authorized administrator of Iowa State University Digital Repository. For more information, please contact [digirep@iastate.edu](mailto:digirep@iastate.edu).

SF971  
J72C  
C. 2

CLINICAL AND PATHOLOGIC STUDIES  
OF A DERMATITIS OF IMMATURE IOWA SWINE

by

Lloyd Diehl Jones

A Thesis Submitted to the  
Graduate Faculty in Partial Fulfillment of  
The Requirements for the Degree of  
MASTER OF SCIENCE

Major Subject: Veterinary Pathology

---

Signatures have been redacted for privacy

Iowa State College

1955

1495790

## TABLE OF CONTENTS

	Page
I. INTRODUCTION. . . . .	1
II. REVIEW OF LITERATURE. . . . .	3
III. METHODS OF PROCEDURE. . . . .	8
A. General Procedures. . . . .	8
B. Tissue Techniques . . . . .	9
C. Staining Methods. . . . .	10
D. Controls. . . . .	11
IV. RESULTS . . . . .	13
A. Definition. . . . .	13
B. Etiology. . . . .	13
C. Incidence . . . . .	13
D. Predisposing Factors. . . . .	14
E. Pathogenesis. . . . .	15
F. Gross Pathology . . . . .	17
G. Histopathology. . . . .	18
1. Skin . . . . .	18
2. Lymph nodes. . . . .	22
3. Spleen . . . . .	23
4. Liver. . . . .	23
5. Kidney . . . . .	23
H. Bacteriologic Findings. . . . .	24
V. DISCUSSION. . . . .	25
VI. SUMMARY AND CONCLUSIONS . . . . .	30
VII. LITERATURE CITED. . . . .	33
VIII. APPENDIX: CASE HISTORY FORM. . . . .	38
IX. FIGURES . . . . .	39
X. ACKNOWLEDGMENTS . . . . .	82

## I. INTRODUCTION

Almost fifty years ago Melvin (1907) wrote,

Affections of the skin in hogs are very common; and as some of the skin lesions are frequently associated with infectious diseases, a thorough knowledge of the various cutaneous affections is of great importance from the standpoint of a differential diagnosis.

Excepting parasitism, viral exanthemata, swine erysipelas, and photosensitization, little has been accomplished in fulfilling this need so aptly stated. Malkmus (1910) believed the condition of the skin indicated the state of health. "If the condition of the hair coat is bad, notwithstanding good care and shelter, it may be assumed that the animal is suffering from ill health." Cipollaro and Schwartz (1954) felt that skin diseases, with few exceptions, are an expression of derangement of the normal physiology of the organism. "Many pathologic states--metabolic, endocrine, infectious or malignant--frequently manifest themselves first in the skin."

During the past few years a skin disease of suckling pigs has been reported with increasing frequency in Iowa. Names employed in reports include "pustular dermatitis", "greasy pig", "necrotic dermatitis", "infectious dermatitis", "eczema", "exfoliative dermatitis", and "exudative dermatitis". Among Middle Western swine the incidence of the disease seems to be increasing. In some Iowa droves it has caused serious losses. All of our basic information has been gleaned from reports of studies made by continental workers. A great deal of information is still lacking concerning details of this disease including predisposition, etiology, pathogenesis, lesions, and symptoms. It is uncertain whether this is a specific disease or a manifestation held in common by several diseases.



This study was undertaken in hope that it would help solve a problem which has confronted the veterinarian for over a century.

## II. REVIEW OF LITERATURE

The literature concerning the disease which is to be described in this thesis is fragmentary. That which is available is incomplete and, in some instances, confusing. Spinola (1842) was the first to publish on the subject. He used the term "Hautauschlag", which means skin rash or "(morbi efflorescentiae cutanae)". He reported that it occurred rarely in swine and that it was recognized as an entity, or it could appear with other diseases such as swine pox, foot and mouth disease, and mange. The uncomplicated form was seldom found. When seen in nursing and weanling pigs it was called a baby pig skin rash. This rash first made its appearance as a formation of small vesicles that occurred in dense clusters on various parts of the body, especially around the eyes. These vesicles soon ruptured and formed a very superficial skin ulcer covered with a brown scab. These lesions seemed to spread and coalesce until the entire body was involved. The eyelids were swollen due to edema, their opening narrowed, and the edges gummed with a suppurative exudate. The tongue was usually "coated". Diarrhea might appear, but constipation was more common. Usually anorexia and salivation preceded the appearance of the skin rash. The early symptoms usually disappeared as soon as the skin lesions appeared. According to Spinola, the cause was attributed to the "rich concentrated ration of the sow or the weaned pigs". He also mentioned having observed a gastritis, the significance of which he did not explain.

In his History of Animal Plagues of North America, Bierer (1939) called attention to the great losses of swine (from numerous causes) in 1869, and, at regular intervals thereafter. There was no reference to dermatitis of swine in his report for the period 1732 to 1915.

Roadhouse and Hayes (1911) probably were the first in North America to recognize this disease. They described several skin diseases, including necrotic dermatitis, phthiriasis, swine pox, erysipelas, and sarcoptic mange, but the details of their report were not clear enough to make an accurate comparison.

Three years later Lynch (1914) reported this disease as "pitch scab", "soot", or "eczema". According to him,

. . .dirty, filthy conditions under which hogs are kept in many instances explained the cause of the disease. In many cases the disease is due to irritating substances contained in the water of wallow holes or in the soil or low-lying pastures.

A non-parasitic "eczema" was rarely seen in swine in the opinion of White (1920). He mentioned a "squamous eczema" which occurred with brown or black crusts, in young unthrifty pigs, hence the name "soot" of young pigs. This form of "eczema" was usually seen in neglected pigs which were kept in insanitary quarters.

The lesions of this disease, described by Joest (1923), do not agree with those of other authors. Thin scales of exfoliation were found on the skin. These scales appeared in many stratified layers, lying loosely on skin which was not much inflamed. Histologically only a few changes were seen: There was a slight edema of the stratum spinosum in which the mosaic pattern was slightly disassociated or distorted. In some places the stratum corneum was elevated by edema; no vesicles were formed, but a flatly elevated lesion showed a slight "parakeratosis". The connective tissue of the corium and of the skin glands was unchanged, and slight vasodilation was observed. Scratching accentuated these changes.



Almost all of the pigs affected by this disease, according to Dettweiler et al. (1924), were young, neglected, weak, anemic, and ill with other diseases. Mange and other forms of dermatitis were often mistaken for this disease which they termed "russ der ferkel" or "ferkelausschlag". They observed that the skin was first grey and lusterless; then the hair and skin--especially of the shanks, breast, belly, eyelids, ears, and often all over the body--became covered with a sticky fatty coating. This coating, they noted, was an accumulation of sebum, which decomposed and turned black. Because of this glandular involvement it was also called seborrhea. The vesicles that formed at this stage, soon ruptured to form ulcers over which a black pitch-like scab soon formed. In a more chronic form the skin was thickened and wrinkled and the lesions might have been confused with swine pox or mange.

Schnyder (1930) believed that when this disease appeared in young pigs, it indicated swine pest had prevailed during the previous months, or that their sires and dams were affected with swine plague.

In the report of Mussemeier and Hofferber (1934), the disease caused trouble "in some places in Prussia".

Transmission experiments were conducted by Klobuk (1935). He found it to be a specific infectious disease, easily transmitted artificially, with recovery resulting in acquired immunity. He successfully transmitted the infection by inoculations with a filtrate prepared from an emulsion of the skin of affected animals. He proposed the name of "exanthema suis exfolians sive exfoliativa", and the causal agent "probably is a virus". The details of his work were not available.

Troxler (1948) studied a disease of pigs he called "ferkelruss", "sootmange", "ferkelgrind", "black grinde", and "eczema". He accumulated data from studies of cooperative swine-raising herdbook records to furnish evidence to support his theory of a congenital predisposition to the disease. This predisposition was traced back to the sixth generation on both paternal and maternal sides. These parent pigs were known to have had as many as three separate attacks, each followed by recovery. His report also included results of studies and experiments with cases encountered in his private practice. The occurrence of the condition was non-seasonal. Pigs were found to be susceptible any time after they were 3-weeks old. Pruritus was observed in all of his patients. Various diets, ration supplements, and medicaments were employed with more or less satisfactory response. Success consistently followed the application of therapy for sarcoptic mange. In summary, he recorded that "russ of piglets" was a disease often beginning with hemoglobinemia, diarrhea, and stunting.

"Crustous eczema" was the term proposed for this disease by Glässer et al. (1950). They felt that it often appeared secondarily to other diseases but, without doubt, it also occurred independently as an entity.

In North Ireland the disease was observed quite commonly by Luke and Gordon (1950). Slight pruritus was observed; usually all of a litter was affected. The mortality rate varied and in some droves entire litters died within a week. "Apart from anemia, which usually is present, no abnormality was observed in the viscera." Bacteriologic studies were negative.

In addition to the preceding information, reports of this disease have been made from Japan by Futamura (1926), from Czechoslovakia by Pekar



(1934), and from Great Britain by Mayall (1939). In the United States, other reports have been made by Kinsley (1921), White (1923), Kernkamp (1952), and Gellen (1954). According to Breed (1954), Moore (1954), Quin (1954), Spear (1954), and many others, this disease has been discussed at veterinary association meetings for the last 20 years.

### III. METHODS OF PROCEDURE

The pigs used for this study were procured through the facilities of the Iowa Veterinary Medical Diagnostic Laboratory. Only a very few of the swine received routinely were affected with the disease described in this paper. After making some requests of practicing veterinarians, sufficient materials for these studies were assured. Several field trips were made. Selection of the material for study was limited to farm-farrowed pigs without apparent complicating conditions.

#### A. General Procedures

A report form (Appendix) was employed for collecting data in addition to the record card routinely used for all cases submitted to the laboratory. In all, the data and materials collected for this study were from 20 droves, comprising 374 litters, and totalling 3055 pigs. Over 40 necropsies were performed.

Immediately following electrocution of the pigs, pieces of skin, approximately 2 cm. x 6 cm. were removed from various parts of the body for histopathologic and other studies. A routine necropsy was next performed. The following other tissues were then collected for histopathologic studies: kidney, liver, spleen; and the prescapular, prefemoral, and superficial inguinal lymph nodes. Routine bacteriologic studies were made of the heart's blood, liver, kidney, spleen; and the prescapular, prefemoral, and superficial inguinal lymph nodes. The inoculum was streaked on blood-agar plates and incubated aerobically at 37° C. The plates were discarded after an observation period of 48 hours.

The tissues collected for the histopathologic studies were taken from 24 pigs representing 17 out of the 20 droves studied during the period from July 3, 1953 to April 22, 1955. This included 63 lymph nodes, and sections from 18 livers, 17 kidneys, two spleens, and 101 pieces of skin.

#### B. Tissue Techniques

Modifications introduced during the course of the work resulted in handling the skin specimens along the lines described by Cowdry (1952) as follows: A very sharp knife was used in removing the pieces of skin. As far as possible these pieces were cut so that the direction of the hair was parallel with either a side or end of the piece. The hair was trimmed with scissors and the specimen wetted with tap water. The piece was then placed, with the epidermis down, on a wooden tongue depressor and held in position with common pins placed at frequent intervals along the margins. The tongue depressor was weighted with pieces of lead and the specimen then placed into a 10 per cent solution of formalin in 0.85 per cent sodium chloride solution buffered with calcium carbonate. After four hours the skin was removed from the board, trimmed with a sharp wet surgical knife and replaced into the fixative with the epidermis down. After 20 hours the pieces were placed in a 70 per cent solution of ethyl alcohol for storage or further processing.

Usually after 24 hours in the 70 per cent alcohol, the pieces of skin were removed for study with the aid of a binocular dissecting microscope. Then about one-third of a piece of the skin was cut off and the remainder returned to the alcohol for storage. The smaller piece was marked for sectioning and the hair closely shorn with fine dissecting scissors. Then



the specimen was consecutively placed into 95 per cent ethyl alcohol for 24 hours; absolute ethyl alcohol for eight hours; chloroform for 12 hours; chloroform-Altman's mixture (paraffin, beeswax, and stearin), kept liquid at 56° C. for four hours; and finally embedded in Altman's mixture. The other tissues were similarly fixed and embedded. All skin sections were cut between seven and ten microns thick. Sections of all other tissues were cut seven microns thick. All sections were fixed onto slides with Mayer's albumen, then stained, and finally mounted in synthetic resin mounting medium.

### C. Staining Methods

All tissues were stained with Delafield's hematoxylin and counter-stained with ethyl eosin.

In addition sections of 51 lymph nodes and 89 pieces of skin (representing 20 out of the 24 pigs and 15 out of the 17 doves,) were stained by the periodic acid-Schiff method (Hotchkiss-McManus stain) as discussed by Kligman et al. (1951), McManus (1948), and Gomori (1952).

Modifications introduced during the course of the work resulted in the following procedures:

1. Xylene	2 minutes
2. Absolute ethyl alcohol	2 "
3. 95% ethyl alcohol	1 "
4. 70% ethyl alcohol	1 "
5. Distilled water	2 "
6. 1% periodic acid	10 "
7. Wash in running tap water	6 "
8. Schiff's reagent	15 "
9. "K" solution	3 "
10. Wash in running tap water	6 "
11. 1% light green solution	1 "
12. 70% ethyl alcohol	0.5 "
13. 95% alcohol	0.5 "

- |  |          |
|--|----------|
| 14. Absolute ethyl alcohol                   | 1 minute |
| 15. Xylene                                   | 2 "      |
| 16. Mount in synthetic resin mounting medium |          |

The Schiff's reagent was prepared according to the methods described by McManus (1948), Lillie (1948), and Pillsbury and Kligman (1951). Modifications introduced during the course of the work resulted in the following procedures:

- |   |         |
|---|---------|
| 1. Boiling distilled water              | 150 cc. |
| 2. Add basic fuchsin                    | 1 gm.   |
| 3. Stir and cool to                     | 55° C.  |
| 4. Filter through coarse paper          |         |
| 5. Cool to                              | 22° C.  |
| 6. Add potassium metabisulfite          | 1.5 gm. |
| 7. N/1 hydrochloric acid                | 15 cc.  |
| 8. Dark storage at 22° C.               | 24 hrs. |
| 9. Add fine activated charcoal          | 0.5 gm. |
| 10. Shake one minute and filter         |         |
| 11. Dark storage at 5° C.               | 48 hrs. |
| 12. Working solution light yellow color |         |

The "K" solution was prepared as follows:

- |                                |         |
|--------------------------------|---------|
| 1. 10% potassium metabisulfite | 5 cc.   |
| 2. N/1 hydrochloric acid       | 5 cc.   |
| 3. Distilled water             | 100 cc. |

#### D. Controls

With each series of sections stained by the periodic acid-Schiff method, at least one section of tissue, known to contain the organisms of aspergillosis, histoplasmosis, or blastomycosis, was carried along in the process as a control.

To obtain normal skin specimens for direct comparison with the abnormal, pieces of skin from 27 different areas were taken from an apparently normal 5-week old pig weighing 20 pounds. These pieces of skin were prepared, fixed, and stained with hematoxylin and eosin in the manner already described.



The histology of the skin of swine has been described by Gurlt (1835), Ellenberger (1906), Kränzle (1912), David (1932), and Ham (1944); the lymph nodes of swine by Richter (1902), Sabin (1905), and Trautmann (1926); the liver of the pig by Mall (1906), and reconsidered by Elias and Lazarowitz (1954); the kidney of the pig by Tereg (1911), and Trautmann and Fiebiger (1949). The cytology of the spleen has been described by Jackson and De Boom (1951). These descriptions were used as a basis for determining the presence of any abnormalities found in the various tissues examined in this study.

#### IV. RESULTS

##### A. Definition

The disease, as a result of observations made in this study, is defined as follows: A specific acute generalized dermatitis involving the entire body surface of young swine characterized by sudden onset and short course; marked by hyperhidrosis, excess sebaceous secretion, exfoliation, exudation, and without pruritus; resulting in loss of skin function, extreme dehydration, rapid exhaustion, usually terminating in death. A secondary bacterial invasion accompanies the process.

##### B. Etiology

The scope of this investigation did not embrace a search for the causative agent. Unfortunately it is still unknown.

##### C. Incidence

The disease is widespread in Iowa and neighboring states. Reports received from many sources indicate its prevalence has increased during the past six years. The disease attacks the young pig at any time between five and 35 days of age. The average age of the pigs studied was 21 days. The youngest pigs had the least resistance as shown by the shorter course of the disease and by a higher morbidity and mortality.

Any number of the litters on a farm may be affected. If the disease appears in a litter, all of the pigs of that litter usually become affected, but this is not necessarily so. On one farm half of each litter was affected.

Out of the 3055 pigs in the study, 881 (28.8%) were reported as having the skin disease. Out of these 881 pigs, 597 (67.8%) were reported as dead at the time specimens were submitted for study. This represents a total mortality rate of 19.5%.

The mortality rate varies greatly. In one drove five out of 81 pigs died, and in another, 145 out of 160 pigs died.

#### D. Predisposing Factors

No predisposing factors could be found. The occurrence was not seasonal. Variations in housing did not make any noticeable difference. None of the case histories studied involved reports of the pigs having been chilled or overheated. No differences were discerned by the use of oat straw, shredded corn stalks, or ground corn cobs for bedding. In most cases the sanitary conditions on the farm were reported as being good.

The feeding programs were considered adequate. Animals that had access to pasturage were as much affected as those maintained on dry lots. The ration of the nursing pigs usually included supplemental creep feeding. Pigs were weaned at an early age in only one drove.

No specificity of the disease was found for breed, sex, color, or size of litter. No evidence could be found to indicate an hereditary influence. Pigs of first, second, and third litters were equally affected. Other diseases, including external parasitisms, did not appear to complicate the clinical picture.



### E. Pathogenesis

At the onset of this disease the pig is listless, the eyes are not as bright as normal, the facial expression is slightly drawn, the ears are not erect, the tail is drooped, the skin is dull, and the hair has lost its luster. Upon stirring the pigs from their nest they appear brighter for a short period of time.

The entire skin surface is covered with thin dry delicate scales. The color of these scales varies with the cleanliness and color of the skin. They appear grey on black skin, reddish-brown or rusty on red skin, and light orange on white skin.

On the second or third day, as the condition progresses, the attitude varies from dejection and apathy to restlessness and anxiety. There is some anorexia and thirst.

The skin is more taut and has a slightly thickened and swollen appearance. This condition can be best observed with the aid of a dissecting microscope. The polygons of the skin pattern are swollen, and their bands of demarcation are more prominent. Tiny brown spots begin to appear at the base of the hairs and at the openings of the sweat glands between the hairs (Fig. 1). These brown spots increase in number and size as the disease process continues. The skin is damp and oily.

As the disease progresses the animal becomes more languid and depressed. The anorexia increases. Constipation is most usual but diarrhea may appear temporarily. There is a loss of body weight. Pyrexia has never been reported as a significant finding. The hair is not damaged and remains intact through all the stages of the disease. Pruritus is not present at

any time. Another unusual feature is that the pigs do not evidence pain even though there is great tissue damage.

The course of the disease from this point on does not always follow the same pattern. Three different forms are observed. For the purpose of description they are designated peracute, acute, and subacute. Transitions and variations between these forms may appear at any time.

Peracute form - At any time after the brown spots appear, the entire body rapidly becomes covered with a wet, sticky, greasy exudate composed mainly of sebum, serum, and sweat. Cutaneous erythema is marked. This process stops abruptly at all the muco-cutaneous junctions where a thick line of gummy exudate forms. The general condition becomes worse. Anorexia is complete. There is rapid dehydration with increased depression and weakness. The production of exudate may cease temporarily and that already present dries forming a thin scab coating. Upon the resumption of exudate production, the formed scab is loosened which is thus readily removed to expose a raw highly inflamed skin. This reaction may be more easily observed in any area where the hair is thin. It was constantly found on the feet of all of the pigs studied involving both the plantar and volar interungulate skin and associated digital bulbs (Fig. 9). The skin may have a strong rancid odor. There is severe emaciation, dehydration, and exhaustion. Death is the usual termination. The entire course may vary in length from three to five days.

Acute form - This form is a little less explosive, but just as spectacular as the peracute form. Instead of the rapid severe outpouring of exudate, the process proceeds in a slower and more constant manner. The brown spots continue to increase in number and size in a most persistent



manner. Tiny vesicles and pustules develop which rupture forming ulcers. Before rupturing, these tiny vesicles and pustules may coalesce, thus undermining larger patches of epidermis. This phenomena can not always be observed grossly, except on the feet. Here it was constantly found on all the pigs studied involving both the plantar and volar interungulate skin and associated digital bulbs (Fig. 10). The skin remains moist and greasy and the exudate accumulates and dries. Large scabs and crusts are formed which fracture along bending furrows and cleavage lines thus forming deep fissures. The skin is more thickened and wrinkled than in the peracute form. Anorexia is complete. Emaciation, dehydration, and weakness is progressive. Death is the usual termination. The entire course varies from four to eight days.

Subacute form - This form is the least commonly encountered. It develops in the same manner as the acute form. The skin becomes more thickened and wrinkled than in the other two forms (Fig. 6). The entire course may require three weeks. If there is recovery it is slowly accomplished. Although the mortality rate is lower than in the other two forms, death may occur at any time.

#### F. Gross Pathology

Upon opening the cadaver one is impressed with its marked state of dehydration and emaciation.

All of the superficial skeletal lymph nodes were enlarged and soft. In many there were peripheral hemorrhages and pigmentation. On sectioning them the cut surface bulged and lymph was released. When the course had

been somewhat prolonged their texture was more firm. Occasionally military necrosis and abscess formation were found.

There was mild cardiac dilatation. The arborization of the coronary vessels were very pronounced. The lungs were usually collapsed and congested. The stomach was usually contracted and contained a small amount of mucus, bile, and sour ingesta. The small intestines were contracted and contained a small amount of chyme, bile, and mucus. The contents of the colon were usually dry and pasty. The liver was usually slightly swollen and cyanotic.

Examination of the urinary system revealed the presence of a precipitate which could be most readily seen impacted in the papillary ducts of the kidneys ("the so-called uric acid infarcts") or lying free in the renal pelvis, ureters, or urinary bladder. This condition duplicates that described by Madsen et al. (1944). They reported this to be associated with acute uremia. This urinary precipitate was found present in every pig examined.

No other significant gross lesions were found.

#### G. Histopathology

1. Skin - All of the pieces of skin collected in this study were examined with a binocular dissecting microscope. These examinations clearly identified and confirmed the presence of the gross lesions described, in addition to some finer details associated with them.

It has been previously noted that the skin appeared swollen. This swelling of the skin was better exemplified by its appearance along the bending furrows and cleavage lines. Furthermore, it was observed at the

openings of the hair follicles. Here the epidermis was pushed up around the hair shaft to a level above the normal skin surface. This condition produced a tiny depression of the skin in the form of a cup around and at the base of the exposed hair. In turn, this cup was filled with a gummy, waxy material, with a ball-like shape, surrounding the base of the hair. This material varied in color from light yellow to dark brown. It was composed mainly of sebum, mixed with cellular debris, bacteria, and "dirt". As the production of this material continued, it accumulated about the base of the hair, spread, and united with its kind from neighboring hairs. This process constitutes the formation of the brown spots at the base of the hairs noted on gross examination.

The brown spots which appeared at the openings of the sweat gland ducts were formed in practically the same manner. These spots were smaller and the materials composing them were sweat, mixed with cellular debris, bacteria, and "dirt".

Upon examining the skin sections of the early stage of the disease with the compound microscope, one is immediately impressed with the severe active hyperemia of the dermis. There is also marked dilatation of the lymphatic capillaries. As the disease progressed the blood and lymph capillaries were even more dilated.

All of the sweat glands were dilated and active. None were in their cyclic resting stage. Their secreting epithelial cells were swollen, the cell membranes indistinct; the nuclei were swollen, finely granular, and many contained two nucleoli. Likewise, the sebaceous glandular activity showed marked increase, in that cellular detail could be recognized in the secretory material contained in the lumen of the gland.



The epidermis showed slight hypertrophy and also hyperplasia as is characterized by a lengthening of the interpapillary pegs. There was a mild increase in the number of layers of cells of the stratum (s.) spinosum. The nuclei of the cells of the s. granulosum were more distinct than found in normal skin. The s. lucidum could not be identified. The hyperplasia of the s. corneum was identified by the increase in its thickness, which contained nuclei, even though individual cellular outline was lost.

There was a moderate increase in the number of eosinophiles in the dermis.

Multiple foci of bacteria, having a coccoid shape and taking the hematoxylin stain, were present on the surface of the skin.

As the disease progressed, there was beginning separation of the epidermis from the dermis indicating edema in this zone. The cells of the s. cylindricum were swollen and their cytoplasmic filaments less distinct. The rate of the epidermal hyperplasia increased. There were focal areas of intercellular and intracellular edema of the s. spinosum. In these areas the tonofibrils were less distinct. At the same time the s. corneum became thicker, cracked, and fissures developed in which bacteria were found. An occasional lymphocyte and neutrophile could be seen, apparently migrating upward through the epidermis. They collected in the vicinity of the bacteria forming tiny pustules in the s. corneum.

In the areas where the intracellular edema existed, the affected cells underwent hydropic degeneration and disintegrated. Simultaneously the intercellular edema separated the cells of the epidermis and tiny vesicles were formed which enlarged and coalesced forming larger vesicles. The

vesicles ruptured, otherwise neutrophiles infiltrated, forming a pustule which could rupture. The vesicles and pustules could be seen any place in the upper half of the epidermis. Throughout this process there was only a very light infiltration in the dermis with leucocytes, principally eosinophiles.

The dermal and epidermal inflammatory changes of the hair follicles proceeded along with that of the neighboring areas, except that pustules and vesicles were not seen. The major portion of the activity was restricted to that part of the follicle above the point where the sebaceous gland duct emptied into it. The accumulation of exudate from this reaction resulted in plugging of the follicle.

If the course of the disease was not terminated by death, the processes described above continued their destruction until the inflammation extended down through the epidermis. The invasion of the dermis first appeared around the lip of the epidermal "cup" at the hair line, forming an ulcer. This so-called cup has already been described. Perhaps this separation is the result of two forces operating simultaneously: one, pressure exerted by the mass of exudate within the cup; and two, the stretching of the epidermis at this point. The perifollicular area of the dermis was infiltrated with leucocytes, primarily neutrophiles. Eosinophiles were more numerous than in the earlier stages. The ulcers at times enlarged peripherally and united with neighboring ulcers. The inflammatory changes in the hair follicles sometimes proceeded below the level previously described and even extended into the base of the hair follicle, the sebaceous gland region, and the sweat gland region.



The severity of the inflammatory reactions varied with the individual animal.

In general, the subacute form of the disease showed the same lesions as the acute form but, in addition, there was a greater amount of epidermal hyperplasia. The interpapillary pegs were longer, wider, and several displayed "clubbing". Compound papillae were also formed in some cases.

The examination of the skin sections stained by the periodic acid-Schiff method failed to reveal the presence of any recognizable specific causative agent.

2. Lymph nodes - The microscopic picture varied somewhat depending upon the severity of the dermatitis and the phase of the disease. There was always marked hyperemia and edema. At the same time there was hyperplasia of the reticular stroma and of lymphoid tissue. This often progressed to the degree that there was compression of both the subcapsular and peritrabecular sinuses. In addition hyperplasia of the reticulo-endothelial cells lining the sinuses was noted. Small areas of hemorrhage were commonly present. The free cellular elements included lymphocytes, free macrophages, a few monocytes, neutrophiles, and plasma cells. Multinucleated giant cells were rarely encountered. The ever present dense population of eosinophiles was outstanding.

As the disease progressed, there were a few small groups of neutrophiles in the cell-poor (medullary) area of the node. In a very few instances these groups of neutrophiles concentrated and enlarged into dense aggregates forming miliary abscesses. The typical picture, however, was that of serous lymphadenitis with eosinophilia.

Examination of the lymph node sections stained by the periodic acid-Schiff method, and by hematoxylin and eosin, failed to reveal any evidence of a recognizable causative agent.

3. Spleen - No abnormalities were noted.

4. Liver - The microscopic findings in the liver were not very significant. Usually there was hyperemia and cloudy swelling. In some livers the sinusoids were normal and in others their lumen was narrowed. The interlobular septa were usually not very distinct, as would be expected in a young animal. Some of the livers showed mild fatty degeneration of the parenchyma. In one specimen necrosis was present in the periphery of some of the hepatic lobules. Except in this one instance no inflammatory reaction was seen. No bacteria were found to be present in any of the sections. In several livers a few neutrophiles were present. Eosinophiles were found in all of the livers.

5. Kidney - Cloudy swelling in varying degree was always present. This involved especially the convoluted tubules. In many instances this process was advanced to coagulation necrosis. In a few specimens there was mild fatty degeneration, first noted in the tubules adjacent to the medullary rays.

Areas of hyperemia were present in a few specimens. There were several petechial hemorrhages in the papillary portion of the renal pyramids in one case.

Nearly all of the kidneys showed dilation of the collecting tubules. There was also moderate dilatation of the glomerular spaces in several instances. In one there was a dilation of the collecting ducts and of the glomerular spaces, with resultant compression of the glomerular tufts.

Some homogeneous and granular precipitate, mixed with fragmented cells and a few erythrocytes, was seen in the collecting tubules and ducts of a few kidneys. (This material is apparently the precipitate reported in the gross findings on page 18. Hence, there is little doubt this condition existed in all the kidneys examined, only to be effaced by the processing procedures.)

Hyperplasia of the epithelium lining the pelvis was always present. This was also seen in the larger collecting ducts of a few kidneys. In addition, many of the pelvic epithelial cells showed hydropic degeneration, ballooning, and desquamation. Their cytoplasm was vacuolated, and contained some fine pale-blue granular material. The other epithelial cells were compressed, contracted, and more deeply stained.

There was a small amount of material in the pelvis composed of precipitated proteins, fragmented cells, and erythrocytes.

An occasional leucocyte was observed in the renal parenchyma or contained in the blood vascular contents.

#### H. Bacteriologic Findings

The bacteriologic studies conducted on the heart's blood and parenchymatous organs produced negative results.

The bacteriologic studies conducted on the lymph nodes resulted in the isolation of microorganisms from two pigs. One case was from an acute form of the disease and the other, the subacute form. The organisms were identified as Micrococcus epidermidis (Winslow and Winslow) Hucker. They fulfilled the criteria for this non-pathogenic organism as outlined in Bergey's Manual of Determinative Bacteriology (1948).



## V. DISCUSSION

This investigation has been limited to the clinical and pathologic aspects of a severe dermatitis of immature Iowa swine. A complete explanation of all the features thus described must await identification of the causative agent. Stokes (1932) has proposed ten main factors that make up the etiologic background of dermatitis. Three of these factors appear most appropriate as applied to the problem concerned in this thesis: First, the metabolic factor; second, the allergic or hypersensitivity factor, either general or specific; and third, the pyogenic factor (virus and bacteria). In addition, a fourth, the mycotic or fungus infection factor, was given consideration, but has been eliminated by use of the periodic acid-Schiff staining methods. To illustrate the first of these three factors, some observations made by nine investigators are presented in the following paragraphs.

During the course of nutritional studies in swine, Hogan (1932) reported the appearance of generalized dermatitis in some of the pigs when they were about 30-days old. His descriptions of the lesions and course of the disease are not complete. Two accompanying photographs are quite clear and illustrate some lesions similar to those described in this paper.

A dermatitis, in some respects similar to the one described in this work, was produced in young pigs maintained on an experimental avitaminosis-A diet by Hentges et al. (1952). Complete details of the skin manifestations were not furnished. In addition to the dermatitis, these pigs exhibited symptoms of a progressive disturbance involving the central nervous system.

Witz and Beeson (1951) produced dermatitis, and other lesions, in pigs on a fat-deficient diet. They described the condition as a scaly

dandruff-like dermatitis on the tail, back, and shoulders; loss of hair (the remaining hair being dull and dry); brown gummy exudate on the abdomen and sides; and necrotic areas on the skin around the neck and shoulders.

The effects on the skin of dogs maintained on a fat-deficient diet were reported by Hansen et al. (1954). Changes observed in the skin included increased mitotic activity of the epidermis, and thickening of all epidermal strata; increased activity of the sebaceous glands producing "greasy skin and hair; and increased activity of the sudoriparous glands". They suggested that dietary fat supplies a factor necessary for the maturation of epithelial, sebaceous, and sudoriparous cells which, when absent from the diet, results in distinct abnormalities in the skin.

Unna (1939) believed there are strong indications that pyridoxine is required by pigs for normal skin growth just as it is required by rats and dogs.

Schreiner et al. (1952) studied 23 human patients with seborrheic dermatitis. Pyridoxine was administered by various methods. They concluded that pyridoxine is metabolically active, or can be converted to a metabolically active substance in the skin. They suggested that a large percentage of patients with seborrheic dermatitis have a metabolic defect in the skin. In a broader sense, their studies present a concept of disease due to a local deficiency state, possibly occurring because of an in-born or acquired metabolic error, which greatly increases the requirement for an essential nutrient.

Chick et al. (1938) conducted some experiments using young white pigs maintained on a "pellagra-producing diet". Generalized dermatitis resulted, along with severe gastro-intestinal disturbances. Their skins



were dirty-yellow in color instead of the rosy-pink of healthy young pigs, and were covered with scabs composed of heaped epithelial cells matted together by "inspissated serum". The administration of riboflavin failed to relieve the condition. Recovery was effected by the use of nicotinic acid.

A study of 80 cases of nutritional enteritis in pigs, obtained from Michigan farms, was reported by Luecke et al. (1949). They presented evidence to indicate that deficiencies of niacin, pantothenic acid, and possibly riboflavin, are involved in producing symptoms of the disease. Their manuscript includes a picture of a group of pigs clearly showing evidence of generalized dermatitis; however, no reference is made to this condition in the text.

Generalized dermatitis, among other lesions, was produced in a group of experimental pigs maintained on a riboflavin-restricted diet by Miller et al. (1954).

It is believed that the preceding nine paragraphs of reports on the development of dermatitis are of significance. Also, it is generally accepted that nutritional diseases of mammals may be reflected through two, and sometimes three, generations. On such a basis, it is believed reasonable to postulate the possibility of cumulative deleterious effects through the generations where so-called marginal circumstances exist which involve nutritional inadequacies.

The role of allergy in domestic animals is to be found in excellent reviews by Brownlee (1940) and Reddin (1949). Considerations of the role of auto-antibodies in diseases of the skin are contained in reports by Zoutendyk and Gear (1951) and Marshall et al. (1951). Weil and Reddin (1943) report some experiments with cattle that revealed the existence of



two different types of antibody. They produced allergy in their cattle with extract of common (short) ragweed (Ambrosia elatior) and thus produced a heat-stabile neutralizing antibody and a heat-labile complement-fixing antibody. They discuss the implications of their concept of the mechanism of supersensitivity and cite reports of other investigators.

A discussion of allergy can never be completed without directing attention to the eosinophile. Excellent reviews regarding this cell have been written by Rebuck (1947), Cape (1952), and Best et al. (1953). Eosinophilia is one of the many features of this spectacular porcine skin disease. It appears early and increases as the disease progresses.

The histopathologic picture of this condition reveals a bacterial flora found to be constantly present on the skin surface as a benign resident, non-invasive, but spreading as the tissues are destroyed. Obviously these organisms are saprophytic, not pathogenic. If they were truly pathogenic, the inflammatory reaction would be equally responsive. The histologic picture did not demonstrate a specific causative agent.

Many features of this disease bear semblance to the diseases known to be caused by both the pox group and the foot and mouth disease group of dermatropic viruses. Collier (1955) and several others, upon viewing Figure 10, immediately stated that it looks just like "V.E." (vesicular exanthema). In contrast to such a view, it is only too simple to suggest a list of viruses of which little is yet known. The possibility of a variant form of a virus should not be neglected. Kelser (1951) was convinced of the potential adaptation of viruses to different host species and different tissues.

This inquiry reveals several questions which require further investigation; the most important of these are as follows:

1. Is the cause a virus which might be revealed by special tissue staining techniques, special tissue culture methods, animal transmission experiments, or egg embryo cultivation?

2. Is this disease one which involves allergy or a hypersensitivity - general or specific - which might be revealed by employing immunological procedures?

3. Is this a disease caused by any of the intermediate group of organisms such as the rickettsiae or pleuropneumonia group?

Further studies of this disease might be enhanced by the use of capillary microscopic examinations of the skin as described by Gilje et al. (1953).

## VI. SUMMARY AND CONCLUSIONS

1. A clinical and pathologic description is presented of a specific acute generalized dermatitis involving the entire body surface of young swine characterized by sudden onset and short course; marked by hyperhidrosis, excess sebaceous secretion, exfoliation, exudation, and without pruritus; resulting in loss of skin function, extreme dehydration, rapid exhaustion, and usually terminating in death. A secondary bacterial invasion accompanies the process.

2. This spectacular disease has been reported with increasing frequency in Iowa and neighboring states. In some Iowa droves it has caused serious losses.

3. The most common names given the disease include "greasy pig", "infectious dermatitis", and "exudative dermatitis". A review of the available literature on the subject is given. In Europe it is most commonly termed "pitch scab", "russ", and "soot".

4. The data and material used in the study were taken from 20 droves, comprising 374 litters, and totalling 3055 pigs. Over 40 necropsies were performed. Bacteriologic studies were made of the parenchymatous organs and the prescapular, prefemoral, and superficial inguinal lymph nodes.

5. Histopathologic studies were made of tissues taken from 24 pigs representing 17 out of the 20 droves processed during the period from July 3, 1953 to April 22, 1955. This included 63 lymph nodes, and sections from 18 livers, 17 kidneys, two spleens, and 101 pieces of skin. Tissues were stained with hematoxylin and eosin. In addition, sections of 51 lymph



nodes and 89 pieces of skin were stained by the periodic acid-Schiff method. This latter method failed to reveal the presence of fungi.

6. The disease affects the pig at any time between five and 35 days of age. The average age of the pigs studied was 21 days. Any or all of the litters on a farm may be affected. If the disease appears in a litter, all of the pigs of that litter usually become affected, but this is not necessarily so. On one farm half of each litter was affected.

7. Out of the 3055 pigs in the study, 881 (28.8%) were reported as having the disease. Out of these 881 pigs, 597 (67.8%) were reported as dead at the time the cases were submitted for study. This represents a total mortality rate of 19.5%. The mortality rate varies greatly.

8. No predisposing factors could be found.

9. The pathogenesis has been outlined. The course of the disease does not always follow the same pattern. Three forms have been described. For the purpose of description they are designated peracute, acute, and subacute. Transitions and variations between these forms may appear at any time.

10. Except for the skin lesions no significant gross lesions were observed at necropsy.

11. The bacteriologic studies resulted in the isolation of microorganisms from the lymph nodes of 2 cases, which were identified as Micrococcus epidermidis, a saprophyte.

12. The microscopic lesions present in the tissues stained with hematoxylin and eosin do not identify a specific causative agent. The histologic features suggest three possible etiologic factors: The

metabolic factor; the allergic or hypersensitivity factor, either general or specific; and, the pyogenic factor (virus and bacteria).

13. Additional studies should be made to ascertain the cause and devise methods of control.

VII. LITERATURE CITED

- Bergey, D. W. 1948. Bergey's Manual of Determinative Bacteriology, edited by Breed, R. S., Murray, E. G. D., and A. P. Hitchens. p. 243. Baltimore, Williams and Wilkins Co.
- Best, W. R., Kark, R. M., Muehrcke, R. C. and M. Samter. 1953. Clinical value of eosinophil counts and eosinophil response tests. Jour. Am. Med. Assoc. 151: 702-706.
- Bierer, B. W. 1939. History of Animal Plagues of North America. With an occasional reference to other diseases and diseased conditions. Baltimore, the author (mimeo).
- Breed, Frank. 1954. Tucson, Ariz. Information on dermatitis of pigs. (Private communication.)
- Brownlee, A. 1940. Allergy in the domestic animals. Jour. Comp. Path. and Therap. 53: 55-74.
- Cape, R. D. T. 1952. The eosinophile cells of the blood. A general review. Edinburgh Med. Jour. 59: 374-384.
- Chick, H., Macrae, T. F., Martin, A. J. P. and C. J. Martin. 1938. III. Curative action of nicotinic acid on pigs suffering from the effects of a diet consisting largely of maize. Biochem. Jour. 32: 10-12.
- Cipollaro, A. C. and P. Schwartz. 1954. The cutaneous manifestations of systemic diseases. New Eng. Jour. Med. 250: 49-53.
- Collier, J. R. 1955. Ames, Iowa. Information on vesicular diseases. (Private communication.)
- Cowdry, E. V. 1952. Laboratory Technique in Biology and Medicine, 3rd ed. Baltimore, Williams and Wilkins Co.
- David, Lorna T. 1932. Histology of the skin of the Mexican hairless swine (Sus scrofa). Am. Jour. Anat. 50: 283-292.
- Dettweiler, Fr., Müller, K. and W. Pfeiler. 1924. Lehrbuch der Schweinezucht mit Die Krankheiten des Schweines. p. 866-867. Berlin, P. P. Verlagsbuchhandlung.
- Elias, H., Bond, E. and A. Lazarowitz. 1954. The "normal" liver of the pig; is it an example of purely portal (and therefore subclinical) cirrhosis? A preliminary report. Am. Jour. Vet. Res. 15: 60-66.
- Ellenberger, W. 1906. Handbuch der Vergleichenden Mikroskopischen Anatomie der Haustiere. Vol. 1. p. 168-173. Berlin, P. Parey.



- Futamura, H. 1926. New cases of contagious pustulous dermatitis of swine (in Japanese) Jour. Jap. Soc. Vet. Sci. 5: 15-20. (Original not available for examination; abstracted in Exp. Sta. Rec. 56: 175. 1927.)
- [Gellen, V. W., editor.] 1954. Greasy skin disease. Corn States Needle. 29: 22. Spring issue.
- Gilje, O. K., O'Leary, P. A. and E. J. Baldes. 1953. Capillary microscopic examination in skin diseases. Arch. Derm. and Syph. 68: 136-147.
- Glässer, K., Hupka, E. and R. Wetzell. 1950. Die Krankheiten des Schweines. Hannover, M. and H. Schaper.
- Gomori, G. 1952. The periodic acid-Schiff stain. Am. Jour. Clin. Path. 22: 277-281.
- Gurlt, E. F. 1835. Vergleichende Untersuchungen über die Haut des Menschen und der Haus-Säugethiere, besonders in Beziehung auf die Absonderungs - organe des Haut - Talges und des Schweisses. Archiv. für Anat., Physio. u. wissenschaft. Med., Berlin. p. 399-418.
- Ham, A. W. 1944. Experimental study of the histopathology of burns: with particular reference to sites of fluid loss in burns of different depths. Annals of Surg. 120: 689-697.
- Hansen, A. E., Sinclair, J. G. and H. F. Wiese. 1954. Sequence of histologic changes in skin of dogs in relation to dietary fat. Jour. Nutr. 52: 541-554.
- Hentges, J. F., Jr., Grumer, R. H., Phillips, P. H., Bohstedt, G. and D. K. Sorensen. 1952. Experimental avitaminosis A in young pigs. Jour. Am. Vet. Med. Assoc. 120: 213-216.
- Hogan, A. G. 1932. Swine reproduction in relation to nutrition. Mo. Agr. Exp. Sta. Res. Bul. No. 168.
- Jackson, C. and H. P. A. De Boom. 1951. A contribution to the cytology of the spleen: the Romanowsky - stained bovine spleen smear. Onderstepoort Jour. Vet. Res. 25: 79-142.
- Joest, Ernst. 1923. Spezielle pathologische Anatomie der Haustiere. Vol. 3. Berlin, R. Schoetz.
- Kelser, R. A. 1951. Adaptation of viruses to different host species and different tissues. Univ. Penn. Vet. Ext. Quarterly No. 121: 31-43.
- Kernkamp, H. C. H. 1952. Weeping skin disease of baby pigs - seborrhea oleosa. No. Am. Vet. 33: 116.

- Kinsley, A. T. 1921. Swine Practice. p. 244-245. Chicago, Am. Vet. Publ. Co.
- Kligman, A. M., Mescon, H. and E. D. De Lamater. 1951. The Hotchkiss-McManus stain for the histopathologic diagnosis of fungus diseases. Am. Jour. Clin. Path. 21: 86-91.
- Klobuk, A. 1935. K problému osutiny selat ("Rust" or soot in pigs). (in Czechoslovakian). Zverlék Rozpravy 9: 257-260. (Original not available for examination; abstracted in Vet. Bul. 7: 130. 1937.)
- Kránzle, Eduard. 1912. Untersuchungen über die Haut des Schweines. Archiv für Mikroskopische Anatomie (Bonn). 79: 525-559.
- Lillie, R. D. 1948. Histopathologic Technic. p. 88-90 and 143-146. Philadelphia, Blakiston Co.
- Luecke, R. W., Thorp, F., Jr., McMillen, W. N., Dunne, H. W. and H. J. Stafseth. 1949. A study of B-vitamin deficiencies in pigs raised on farms. Mich. Agr. Exp. Sta. Tech. Bul. No. 211.
- Luke, D. and W. A. M. Gordon. 1950. Observations on some pig diseases. An eczematous condition of suckling pigs. Vet. Rec. 62: 179-185.
- Lynch, C. F. 1914. Diseases of Swine. p. 617-619. Philadelphia, W. B. Saunders Co.
- Madsen, L. L., Earle, I. P., Heemstra, L. C. and C. O. Miller, 1944. Acute uremia associated with "uric acid infarcts" in the kidneys of baby pigs. Am. Jour. Vet. Res. 5: 262-273.
- Malkmus, Bernard. 1910. Clinical Diagnostics of Internal Diseases of Domestic Animals. p. 43-44. English edition. Chicago, A. Eger. 1912.
- Mall, F. P. 1906. A study of the structural unit of the liver. Am. Jour. Anat. 5: 227-308.
- Marshall, J., Zoutendyke, A. and J. Gear. 1951. Serum auto-antibodies in diseases of the skin. So. Afr. Med. Jour. 25: 764-767.
- Mayall, G. 1939. Some skin ailments of pigs. Vet. Jour. 95: 443-445.
- McManus, J. F. A. 1948. Histological and histochemical uses of periodic acid. Stain Technol. 23: 99-108.
- Melvin, A. D. 1907. Urticaria. U. S. Dept. Agr. 24th Ann. Rpt. of the Bureau of Animal Industry. p. 45-46. 1909.



- Miller, E. R., Johnston, R. L., Hoefler, J. A. and R. W. Luecke. 1954. The riboflavin requirement of the baby pig. Jour. Nutr. 52: 405-413.
- Moore, R. G. 1954. Dunlap, Iowa. Information on dermatitis of pigs in Iowa. (Private communication.)
- Mussemeier and Hofferber. 1934. Annual veterinary reports of the Prussian State veterinarians for 1931-1932 (in German). Part 2. Berlin, R. Schoetz. (Original not available for examination; abstracted in Vet. Bul. 5: 863-866.)
- Pekar, J. 1934. Pemphigus porcellorum (eczema in piglets). (in Czechoslovakian). Zverolek. obzor. Brunn. 27: 263-266. (Original not available for examination; abstracted in Vet. Bul. 5: 89. 1935.)
- Pillsbury, D. M. and A. M. Kligman. 1951. A new histochemical tool for the definitive diagnosis of fungus infections. N. Y. Acad. Sci. Trans. II, 13: 145-148.
- Quin, A. H. 1954. Kansas City, Mo. Information on dermatitis of pigs. (Private communication.)
- Rebuck, J. W. 1947. The functions of the white blood cells. Am. Jour. Clin. Path. 17: 614-630.
- Reddin, L. Jr. 1949. A classification of allergic diseases and their specific manifestations in animals. Ann. N. Y. Acad. Sci. 50: 692-704.
- Richter, J. 1902. Vergleichende Untersuchungen über den mikroskopischen Bau der Lymphdrüsen von Pferd, Rind, Schwein, und Hund. Archiv für Mikrosk. Anat. und Entwicklungsgeschichte. 60: 469-514.
- Roadhouse, C. L. and F. M. Hayes. 1911. Report of live stock conditions in Imperial County, California. Calif. Agr. Exp. Sta. (Berkeley) Bul. No. 219.
- Sabin, F. R. 1905. The development of the lymphatic nodes in the pig and their relation to the lymphatic hearts. Am. Jour. Anat. 4: 355-389.
- Schnyder, O. 1930. Russ der Ferkel. In Stang, V. and D. Wirth, eds. Tierheilkunde und Tierzucht. 8: 675-676. Berlin, Urban und Schwarzenberg.
- Schreiner, A. W., Slinger, W., Hawkins, V. R. and R. W. Vilter. 1952. Seborrhoeic dermatitis: a local metabolic defect involving pyrodoxine. Jour. Lab. Clin. Med. 40: 121-130.



- Spear, M. L. 1954. Ames, Iowa. Information on dermatitis of pigs. (Private communication.)
- Spinola, J. 1842. Die Krankheiten der Schweine. Berlin. Verlag Hirschwald. (Original not available for examination; copy of pages 146-148 very graciously furnished by Dr. A. H. P. van Oosterwijk Bruyn, Rijks University, Utrecht, Holland.)
- Stokes, J. H. 1932. The complex of eczema. Jour. Am. Med. Assoc. 98: 1127-1133.
- Tereg, J. 1911. Der uropoetische Apparat. In Ellenberger, W., ed. Handbuch Der Vergleichenden Mikroskopischen Anatomie Der Haustiere. Vol. 2. p. 241-267. Berlin, P. Parey.
- Trautmann, A. 1926. Die Lymphknoten (Lymphonodi) von *Sus scrofa*, insbesondere deren Lymphstrom - Färbungs - und Ruchbildungsverhältnisse. Zeitsch. für Anat. und Entwicklungsgeschichte. 78: 731-755.
- \_\_\_\_\_ and J. Fiebiger, 1949. Fundamentals of the Histology of Domestic Animals. English edition. Ithaca, N. Y., Comstock Publ. Associates. 1952.
- Troxler, Jost. 1948. Untersuchungen über den Russ der Ferkel. Univ. Bern Inaug. Dissertation. Sursee, J. Lustenberger. 1949.
- Unna, K. 1939. Skin lesions in animals accompanying deficiencies in the vitamin B complex, particularly vitamin B<sub>6</sub>. Jour. Am. Vet. Med. Assoc. 95: 467.
- Weil, A. J. and L. Reddin, Jr. 1943. Dermal supersensitivity, heat-labile, and heat-stabile antibody against ragweed in cattle. Jour. Immunol. 47: 345-352.
- White, D. S. 1920. A Text-Book of the Principles and Practice of Veterinary Medicine. Philadelphia, Lea and Febiger.
- White, T. P. 1923. Diseases, ailments, and abnormal conditions of swine. U. S. Dept. Agr. F. Bul. No. 1244.
- Witz, W. M. and W. M. Beeson. 1951. The physiological effects of a fat-deficient diet on the pig. Jour. An. Sci. 10: 112-128.
- Zoutendyk, A. and J. Gear. 1951. Auto-antibodies in the pathogenesis of disease. A preliminary study of autosensitization of red cells in various diseases. So. Afr. Med. Jour. 25: 665-668.

VIII. APPENDIX: CASE HISTORY FORM

Veterinarian	Address	No.	
Owner	Address	Date	
No.	Ages	No. litters	Age of sows
Total No. farrowed alive	Dead	Weaned	
No. affected pigs	Litters	Losses	
Recent purchases			
Farrowing quarters			
Other housing facilities			
Yards and Pasture			
Ration of sows			
Ration of pigs			
No. years on farm			
Source of stock			
Source of boars			
Medication and vaccinations of sows			
Medication and vaccination of pigs			
Other treatments, sprays, insecticides, wood chemicals, rodenticides, paints, garbage			
History, symptoms, course			
Seasonal occurrence			
Diseases in locality			
Other information			

IX. FIGURES



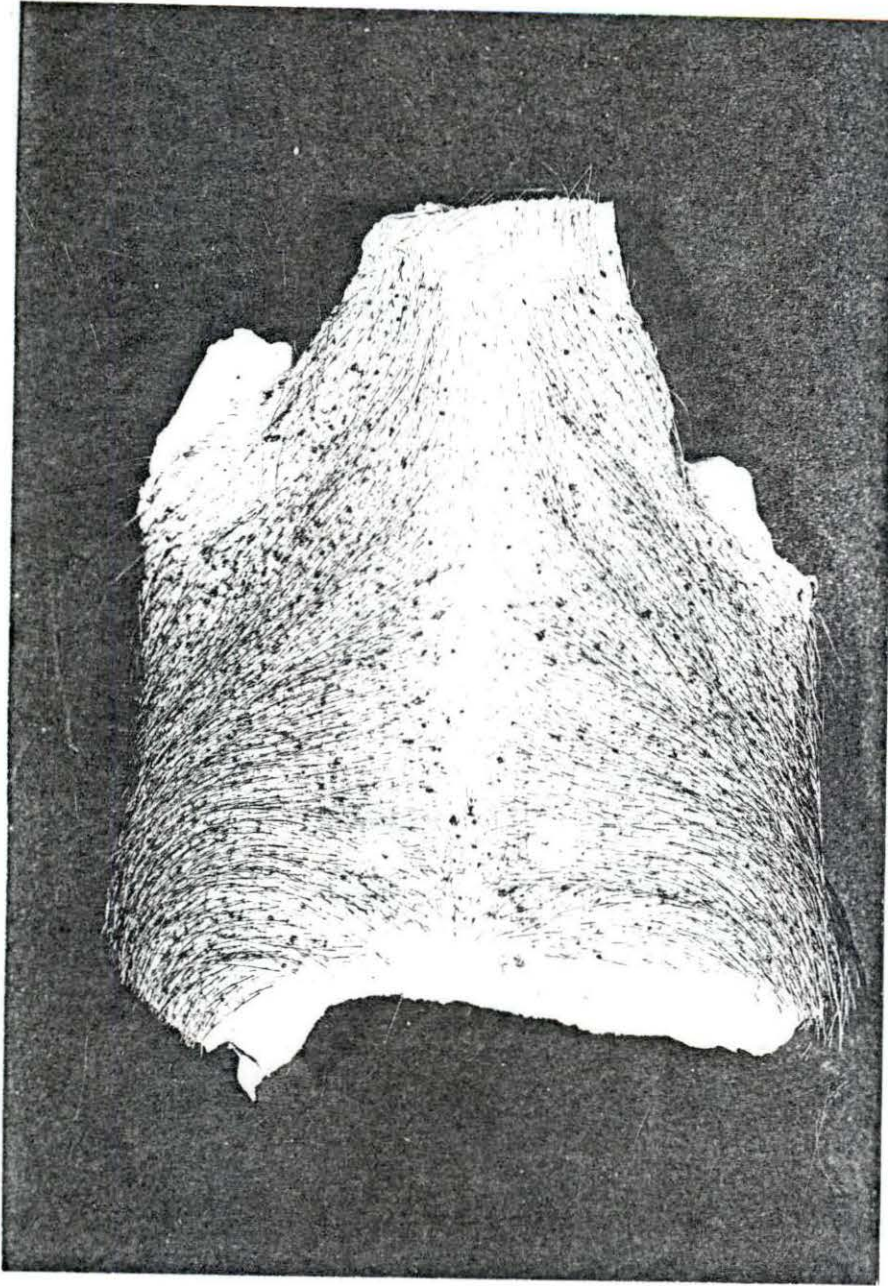


Fig. 1 Sternal area showing skin lesions typical of the very early stage of the disease. Actual size.



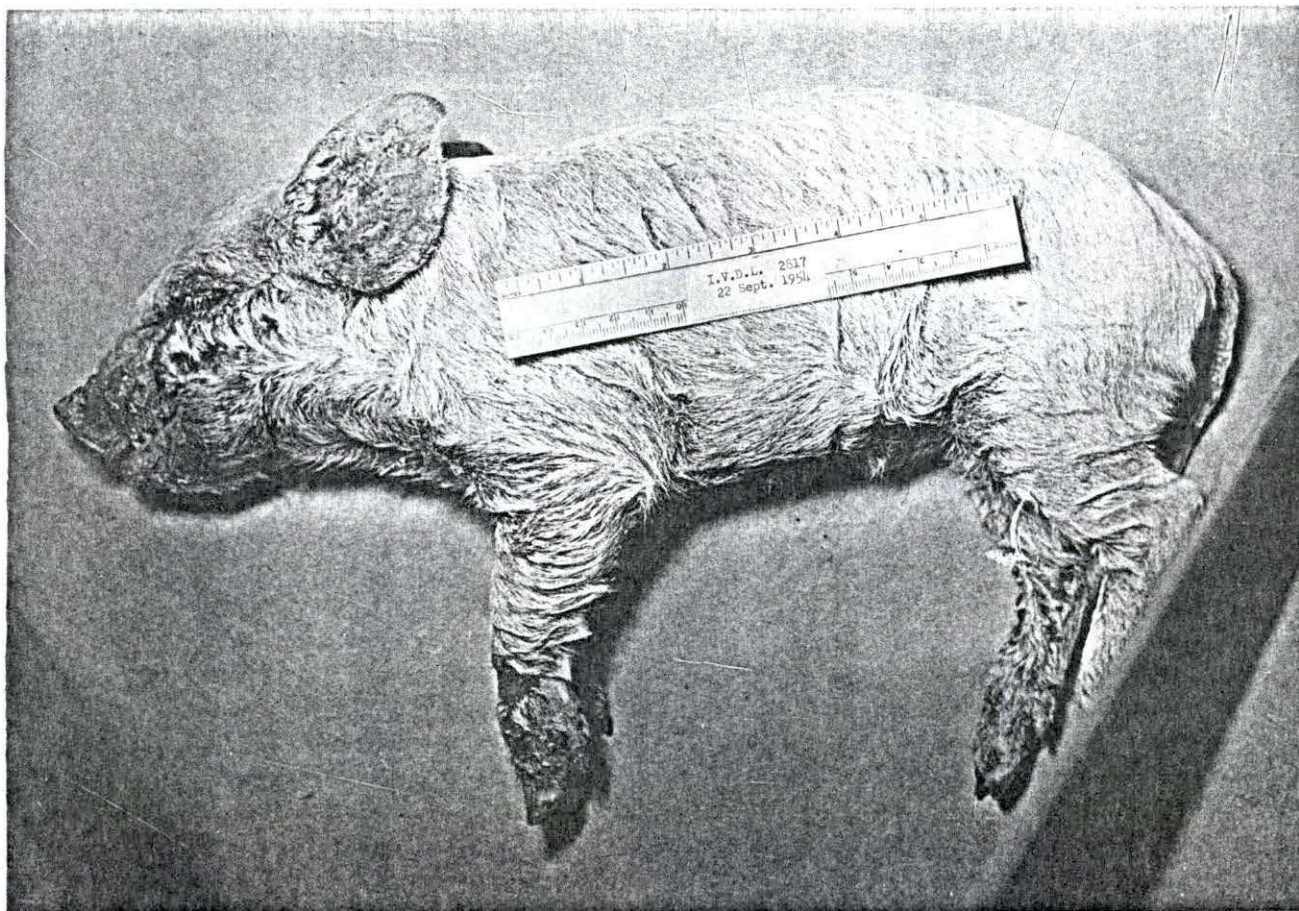


Fig. 2 Moribund pig, approximately 16-day old, showing the dermatitis syndrome. Acute form.

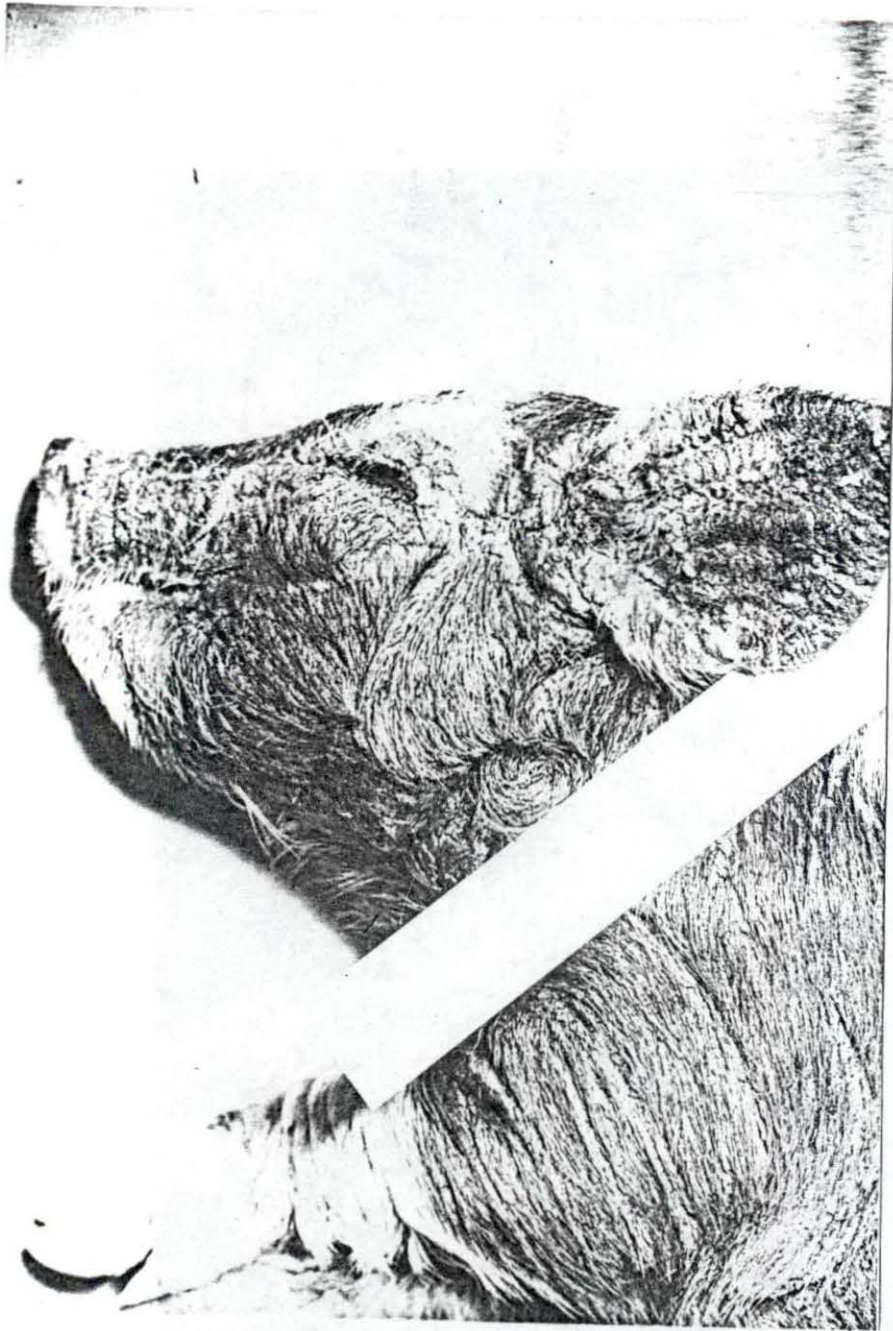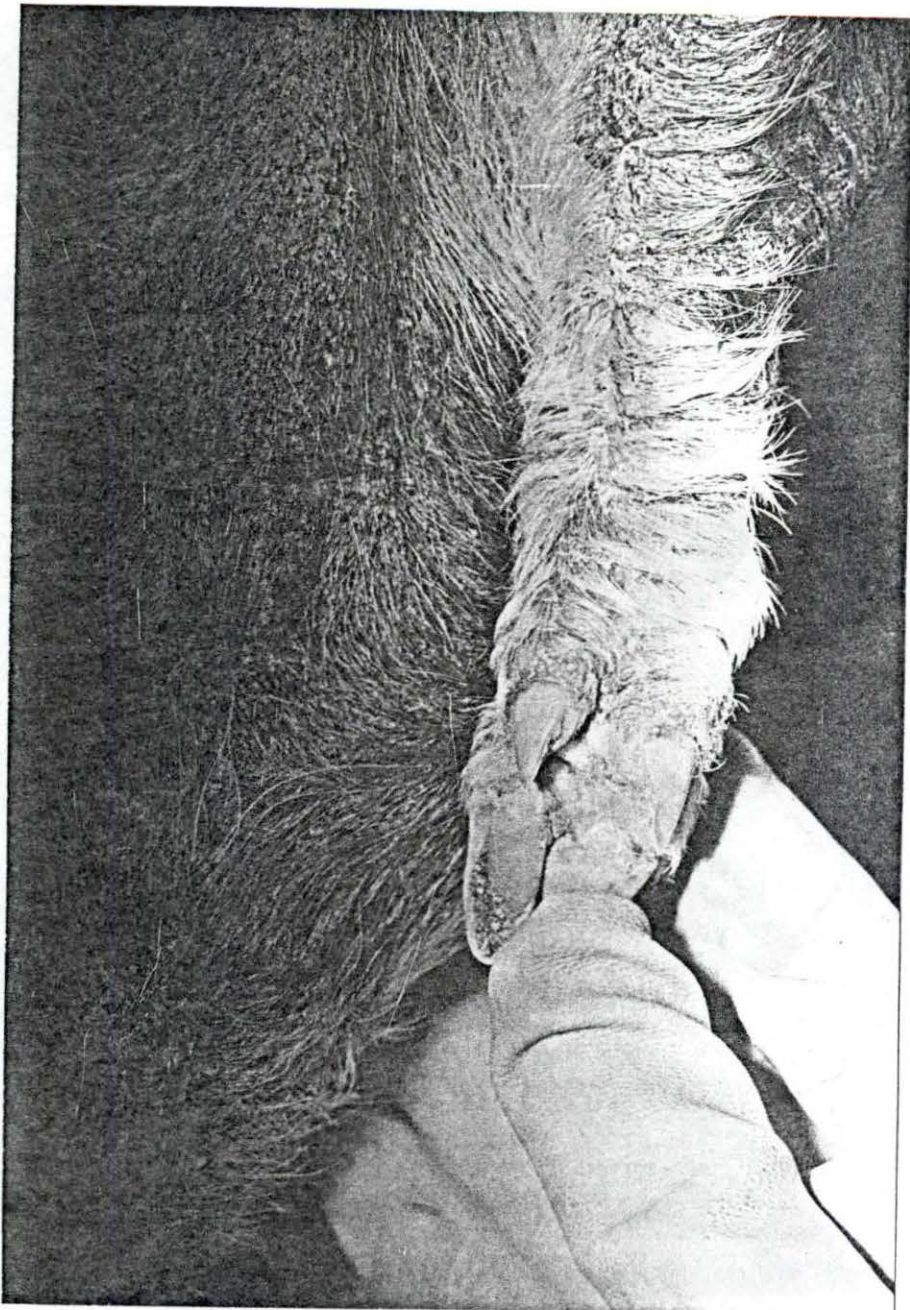


Fig. 3 Head view of a litter-mate of pig shown in Fig. 2.



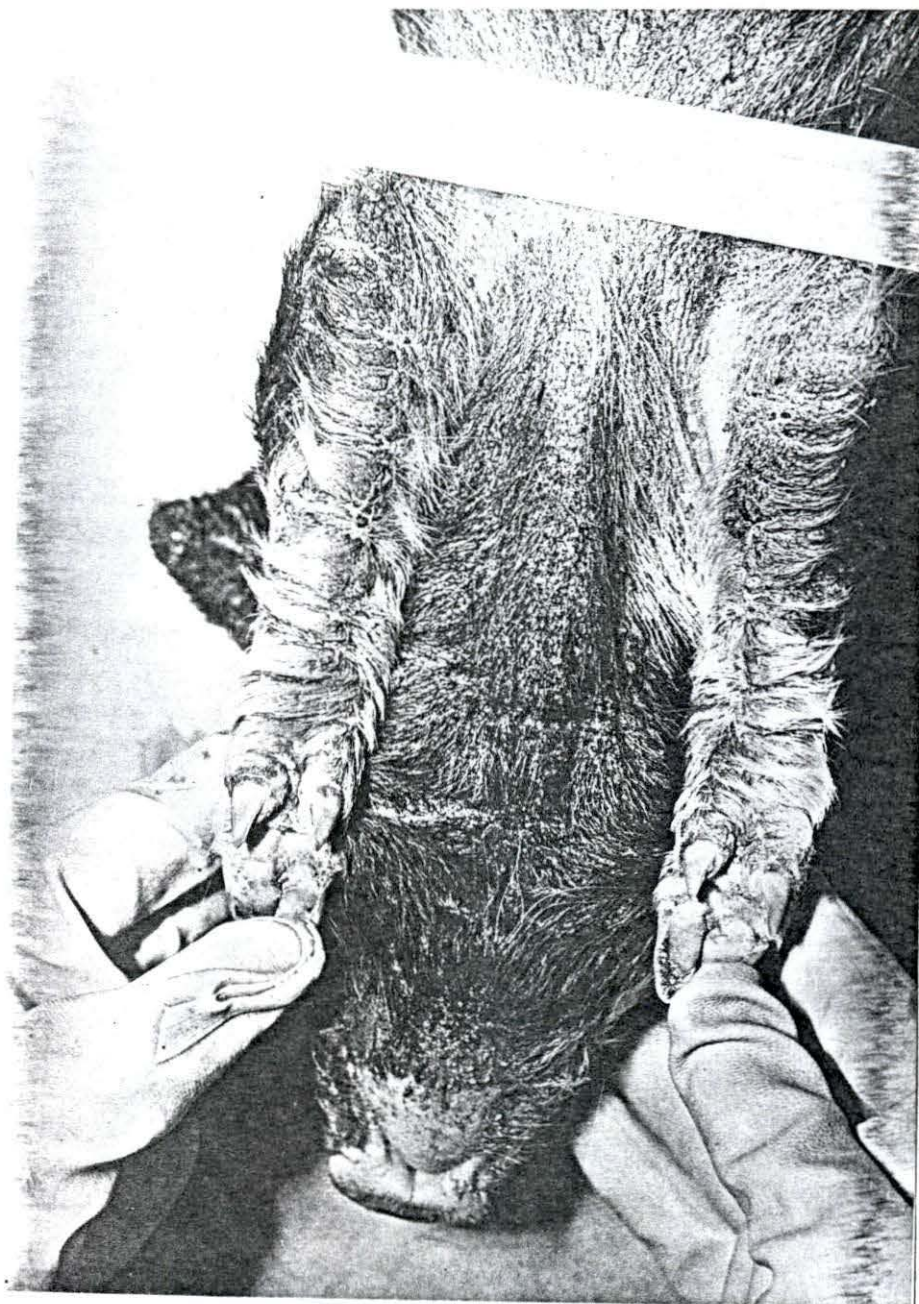

Fig. 4 Antero-ventral view of same pig shown in Fig. 3.



'Fig. 5 Enlargement of portion of Fig. 4.



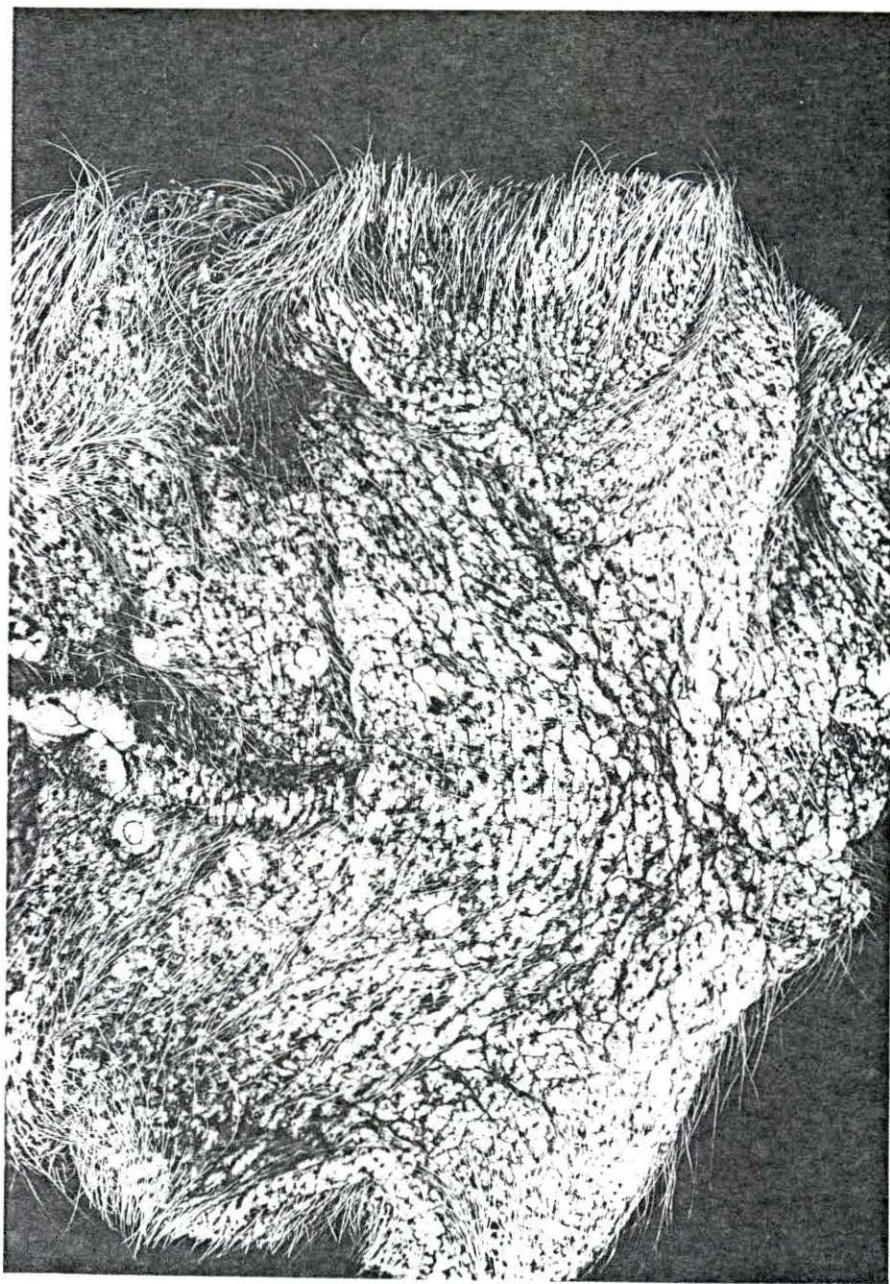

Fig. 6 Sternal area showing skin lesions of the  
subacute form. Actual size.



Fig. 7 Color photograph showing well developed lesions of the early phase of the disease.

Fig. 8 The axillary areas shown in this color photograph are very wet and sticky. Acute form.

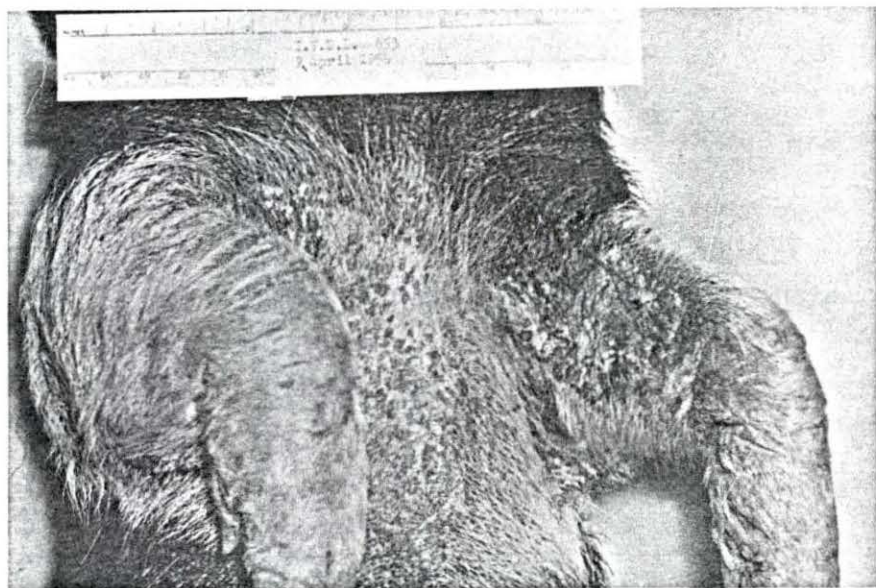
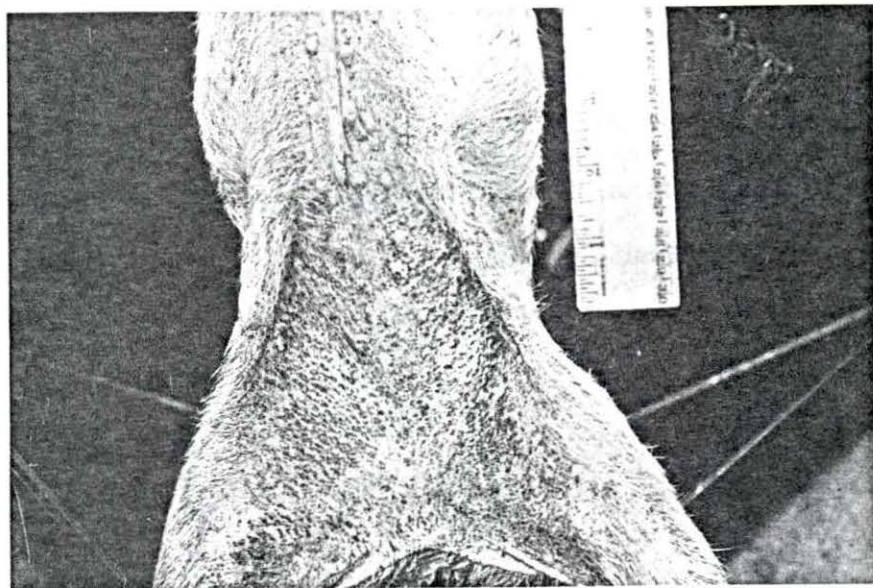
Fig. 9 The lesions on the feet are typical of those described under the peracute form.

Fig. 10 Typical lesions found on the feet in the acute form.



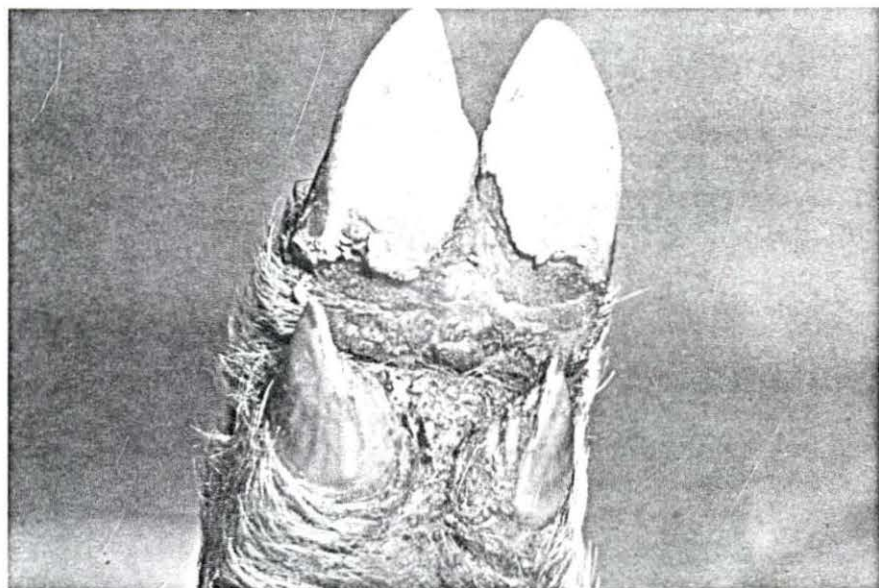
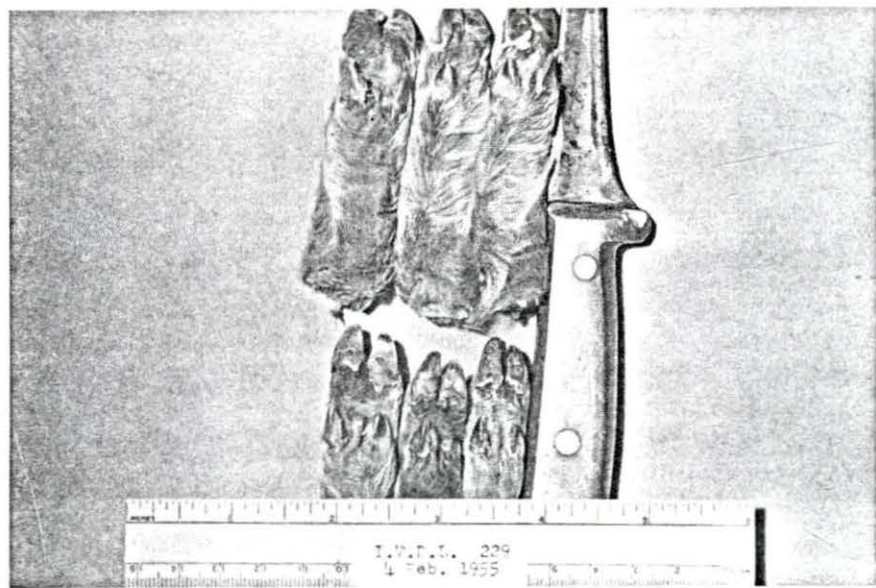


Fig. 11 The numbers are placed to indicate the areas from which pieces of skin were removed for study. Use as a KEY for the photomicrographs appearing on the following pages.

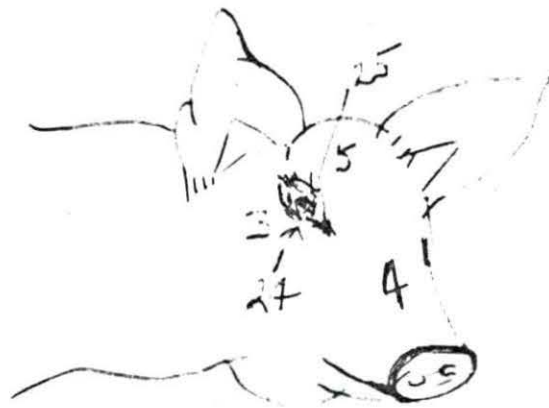
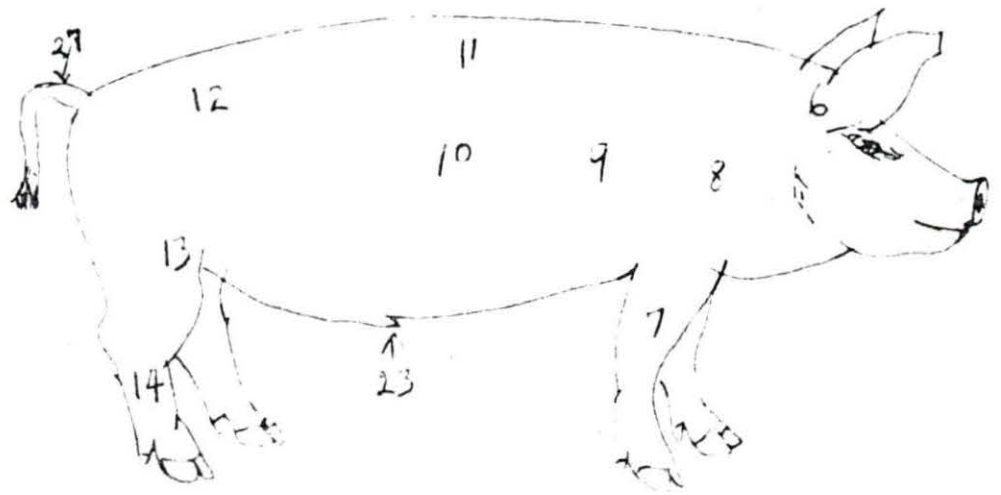




Fig. 12 The disease process has broken through the epidermis above the exposed tip of the tangentially-cut sinus hair. Note the normal pigmentation along the stratum cylindricum. Hematoxylin and eosin stain.\* Area 4. x 35.

Fig. 13 Skin from area 4 of control pig. x 35.

---

\*All the porcine skin photomicrographs were taken from specimens stained with hematoxylin and eosin (see text).

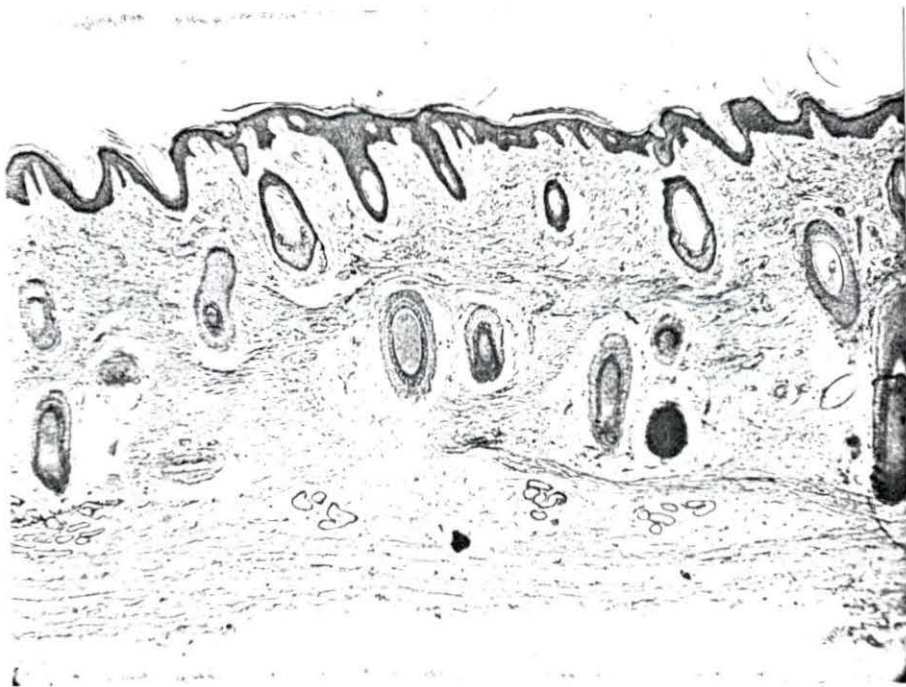
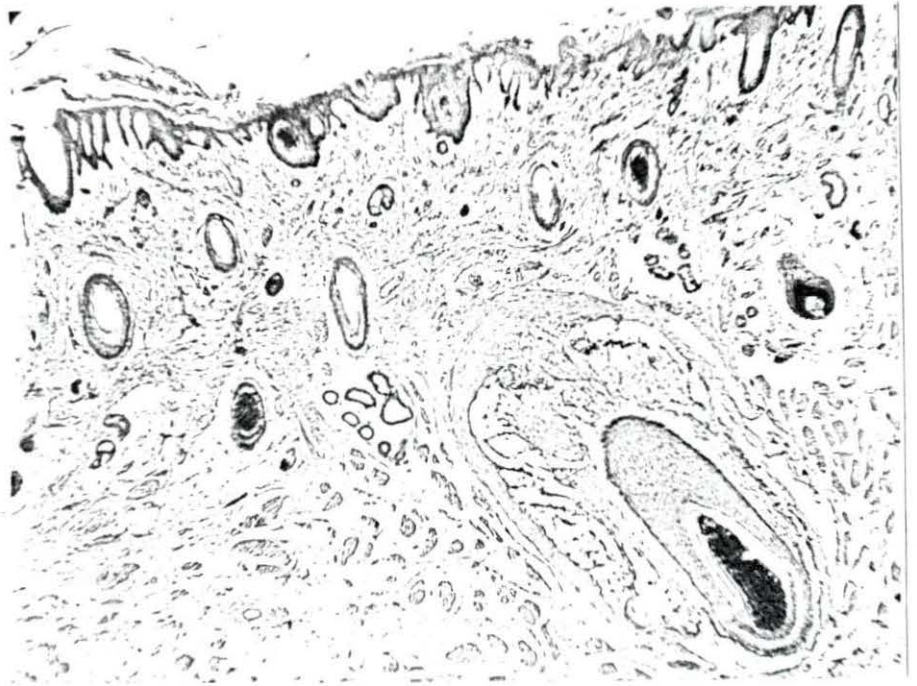


Fig. 14 The very early stage of the disease is indicated by dermal hyperemia and a slight amount of hyperplasia and hypertrophy of the stratum spinosum. Compare with Fig. 25. Also note the sweat glands are not dilated. Area 17. x 90.

Fig. 15 A little later phase of the dermatitis shows increased hyperplasia and hypertrophy of the stratum spinosum with inter and intracellular edema. Nuclei are seen in the thickened stratum corneum. Area 17. x 90.



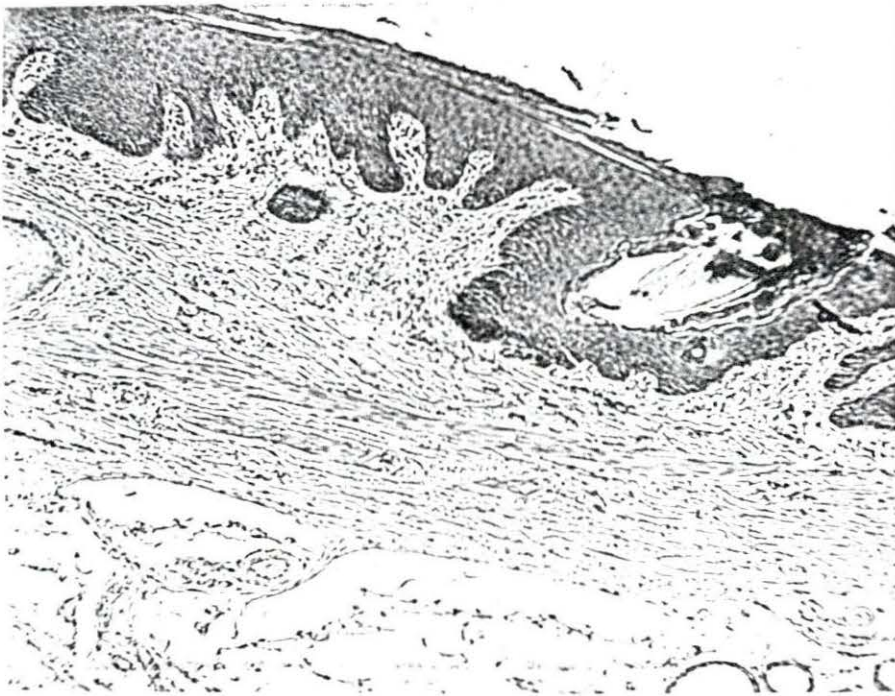
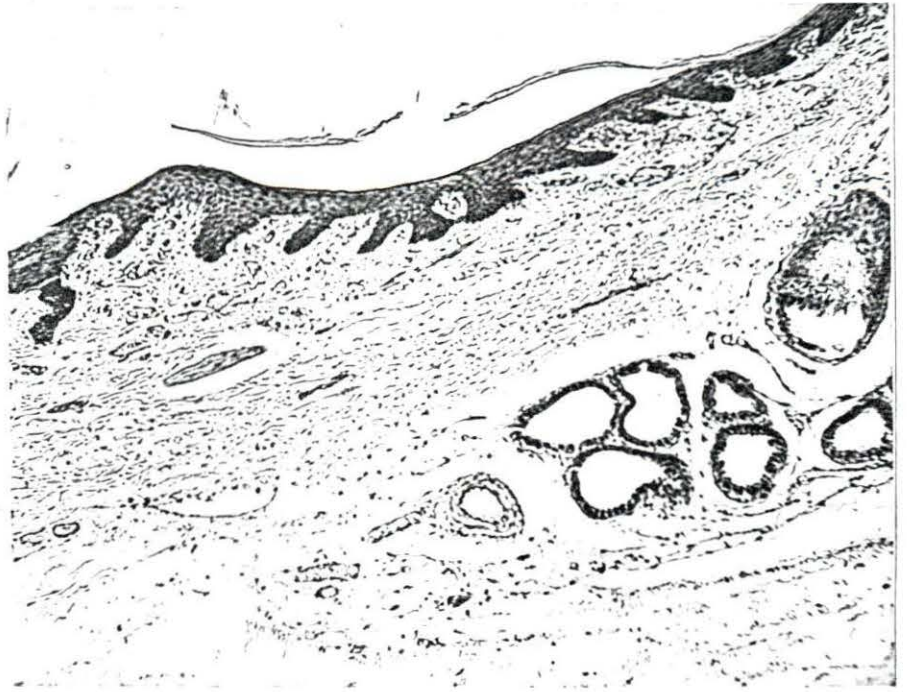


Fig. 16 Lengthening and thickening of the interpapillary pegs are demonstrated in this photomicrograph. Area 2. x 90.

Fig. 17 A photomicrograph, at a higher magnification, of an area shown in Fig. 16 illustrating capillary dilation and hyperemia. Note the nucleated cells in the lumen of the sebaceous gland. Also observe the epidermal pigmentation (normal). x 180.



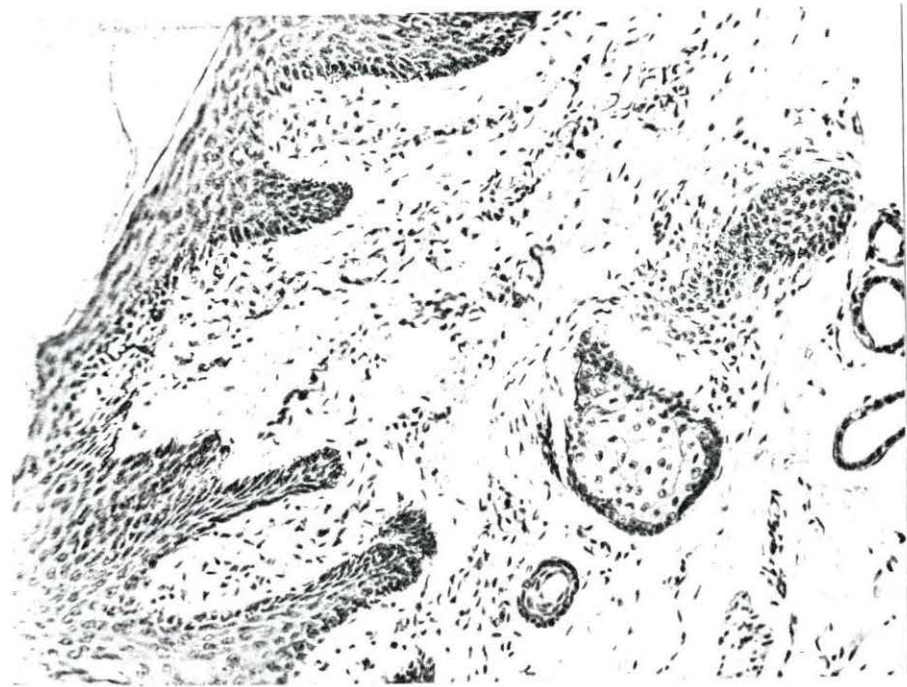
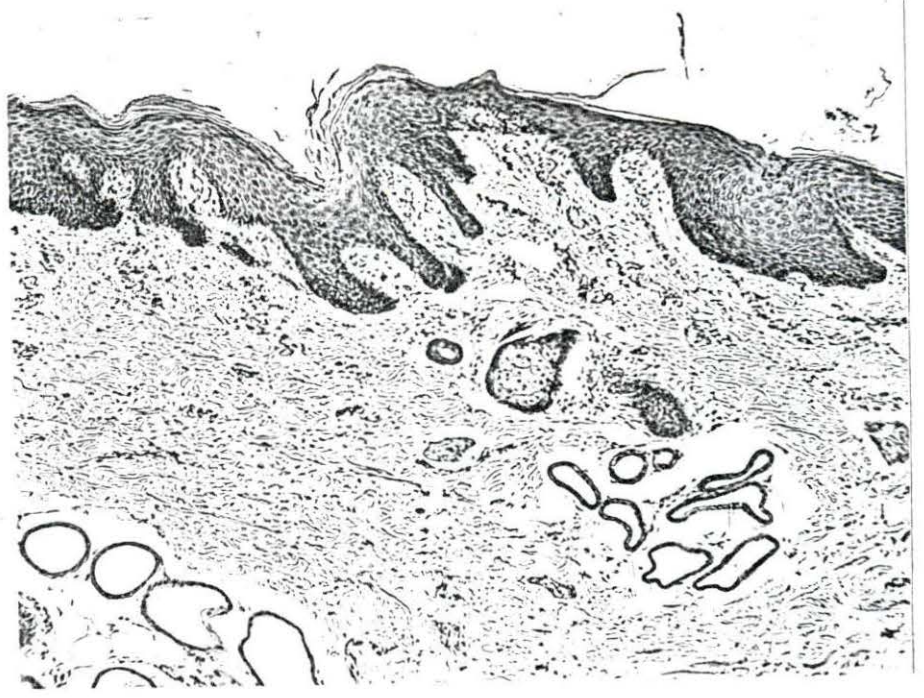




Fig. 18 Skin from area 2 of control pig. x 90.

Fig. 19 Lymph node cut through cell-poor area with eosinophilia.  
Periodic acid-Schiff stain. x 90.


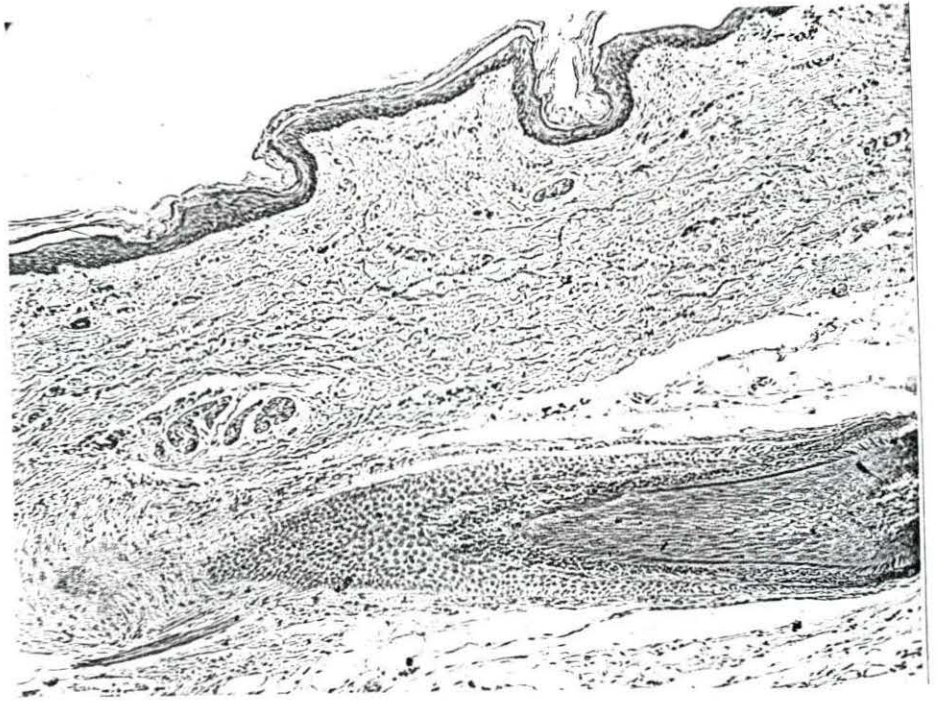


Fig. 20 Two epidermal cups containing a mass of exudate seen grossly as the brown spots described in the text. Pigment (normal) can be seen in the stratum cylindricum. Area 16. x 90.

Fig. 21 Skin from area 16 of control pig. x 90.



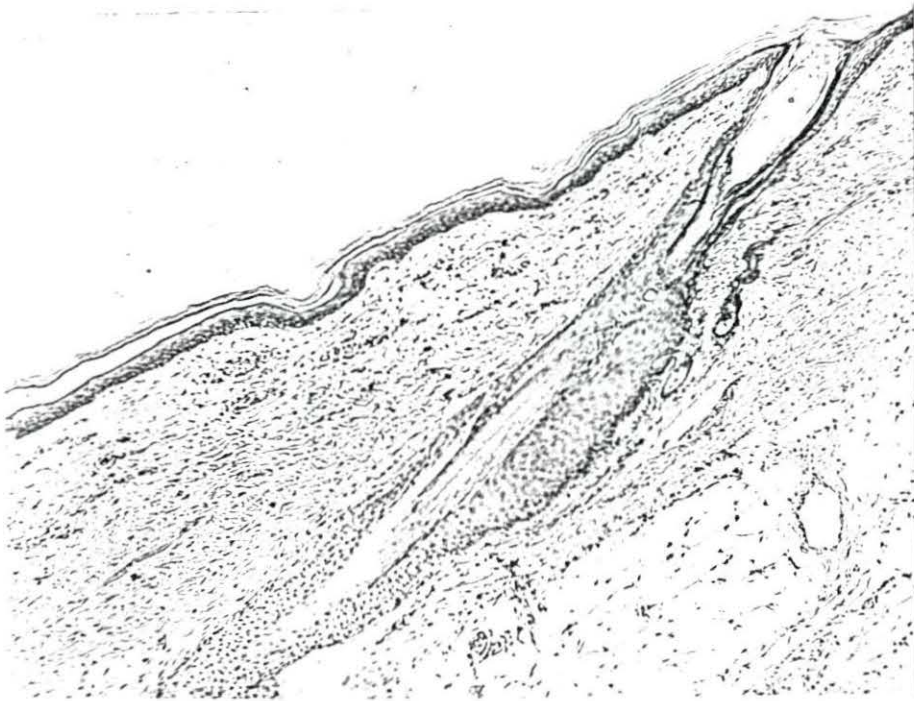
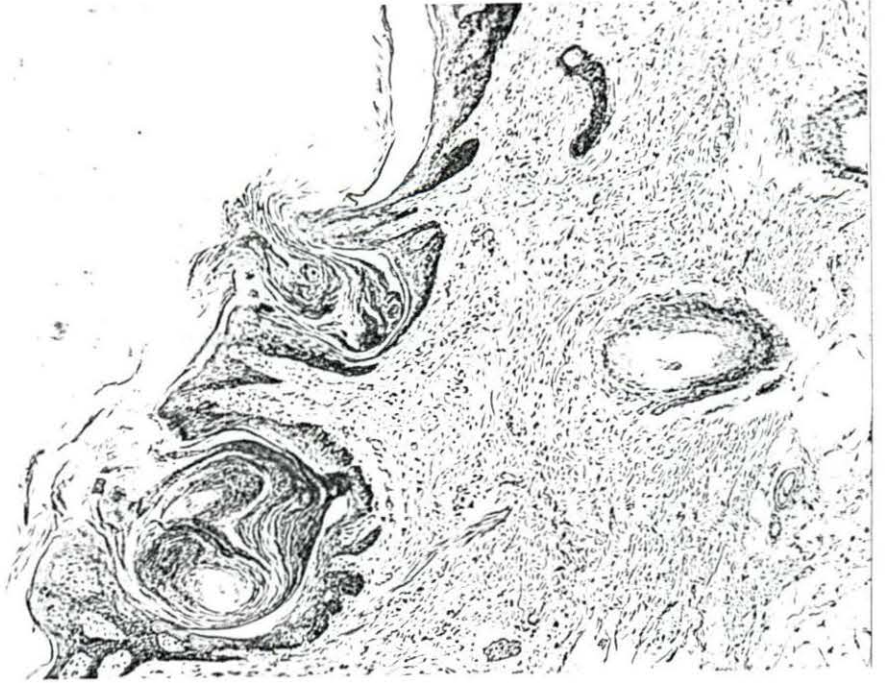


Fig. 22 Photomicrograph again illustrating a mass of exudate within an epidermal cup and another mass surrounding a hair. Again note the nucleated cells within the lumen of the sebaceous glands. Area 1. x 90.

Fig. 23 Skin from area 1 of control pig. x 90.

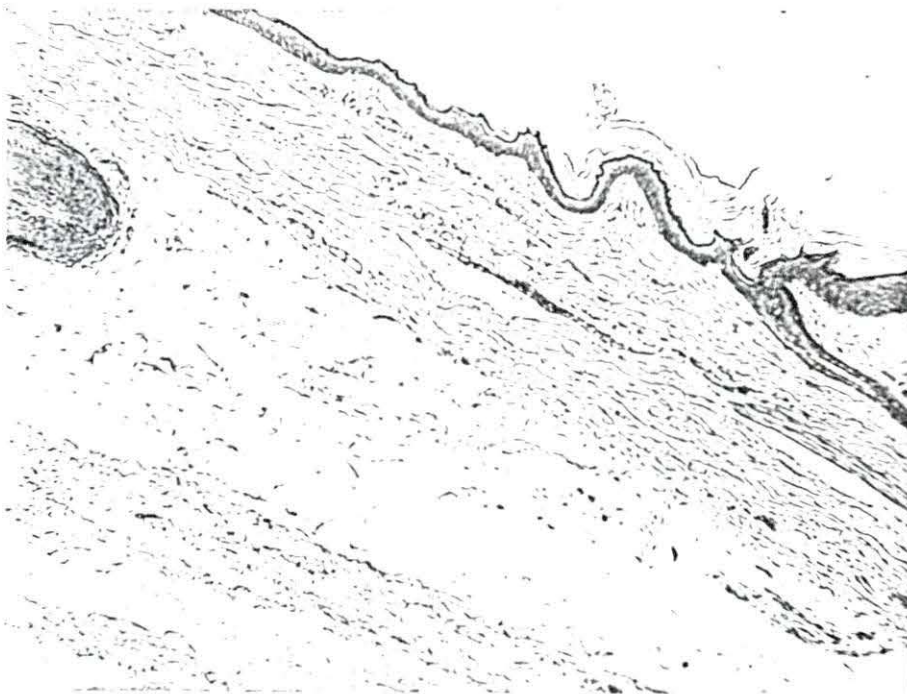
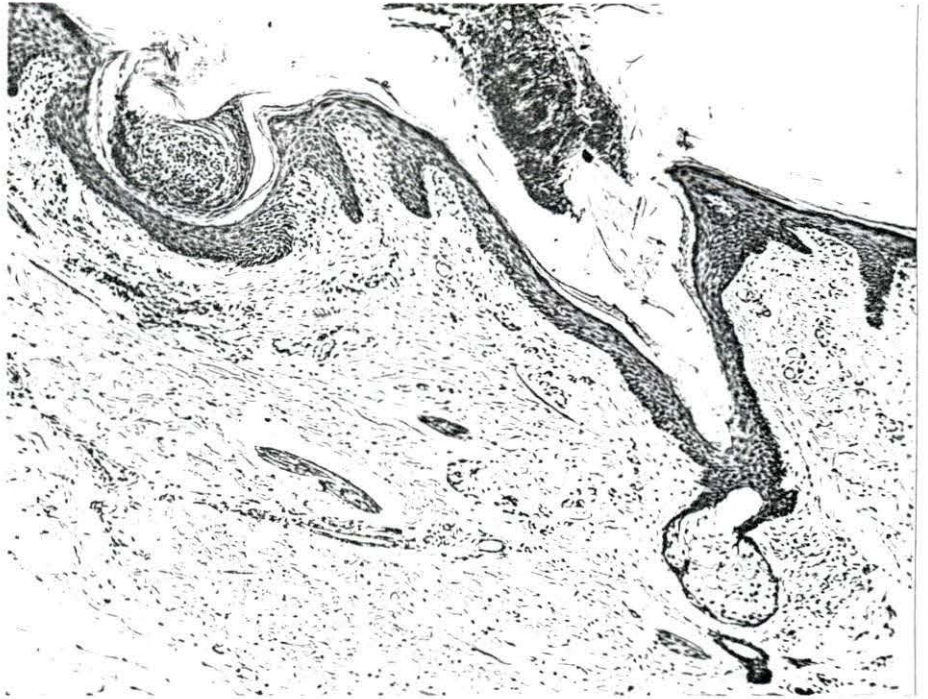


Fig. 24 Total epidermal destruction, seen on the reader's left side of this photomicrograph, results in the formation of a dermal ulcer. Note the leucocytic infiltration in the involved region. Compare with Figs. 14 and 15. Area 17. x 90.

Fig. 25 Skin from area 17 of control pig. x 90.

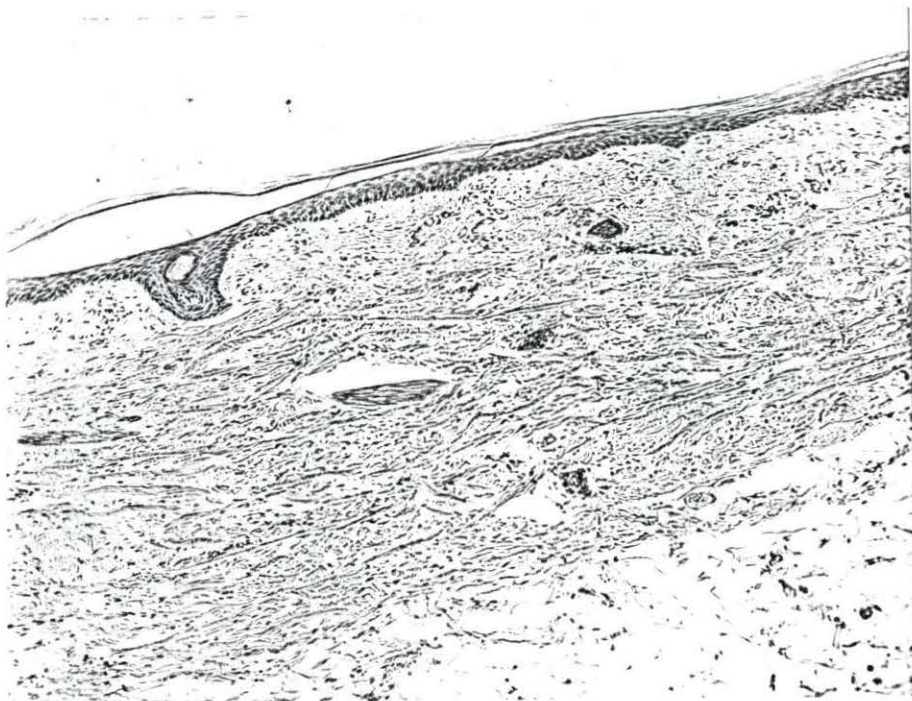


Fig. 26 Extension of the follicular exudate down into the sweat-gland region (upper right). Note the leucocytic infiltration involving the perifollicular region of the tangentially-cut hair. Area 13. x 90.

Fig. 27 Skin from area 13 of control pig. x 90.



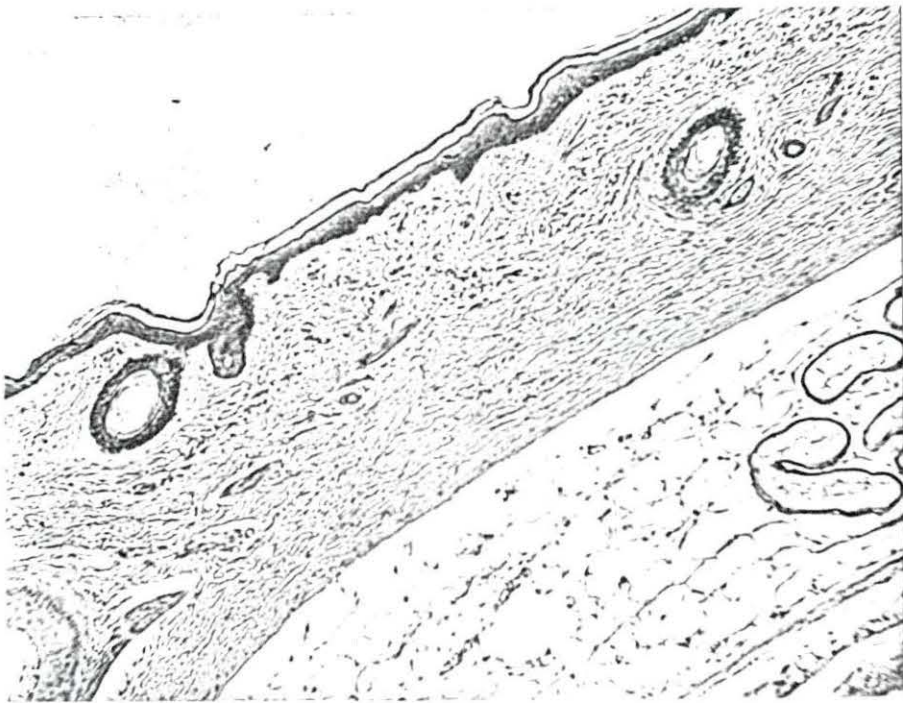
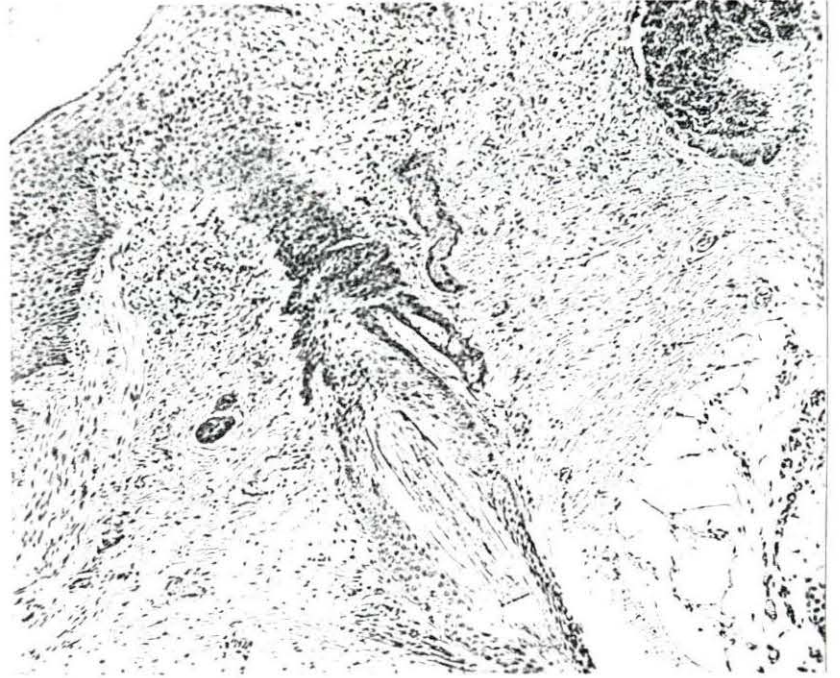


Fig. 28 Compound papillae formation supporting a thick layer of dry exudate. The blood capillaries in the papillary layer of the dermis are greatly dilated and filled with blood. Area 13. x 90.

Fig. 29 Skin from area 12 of control pig. x 90.



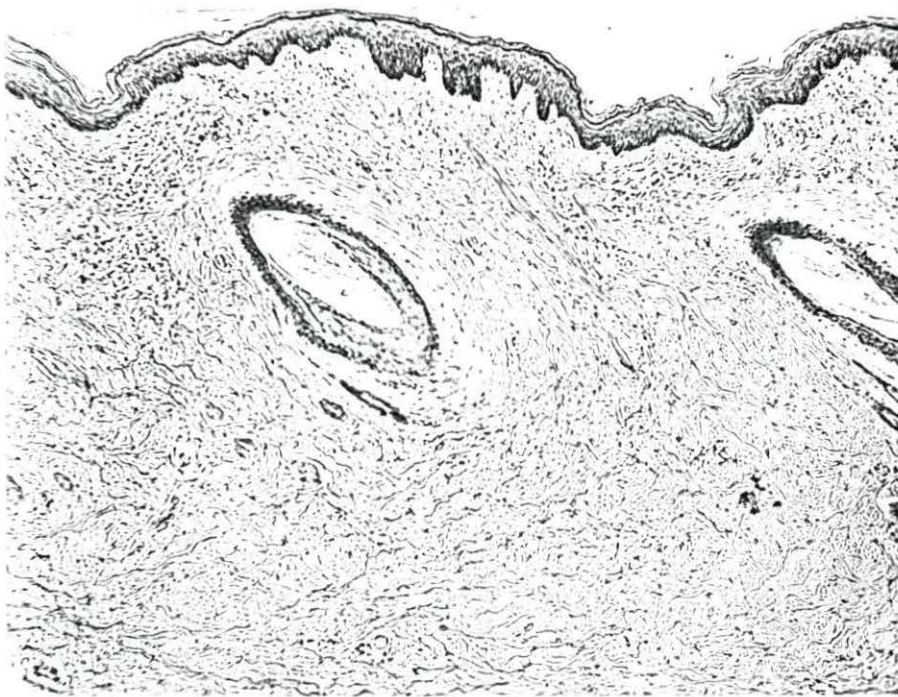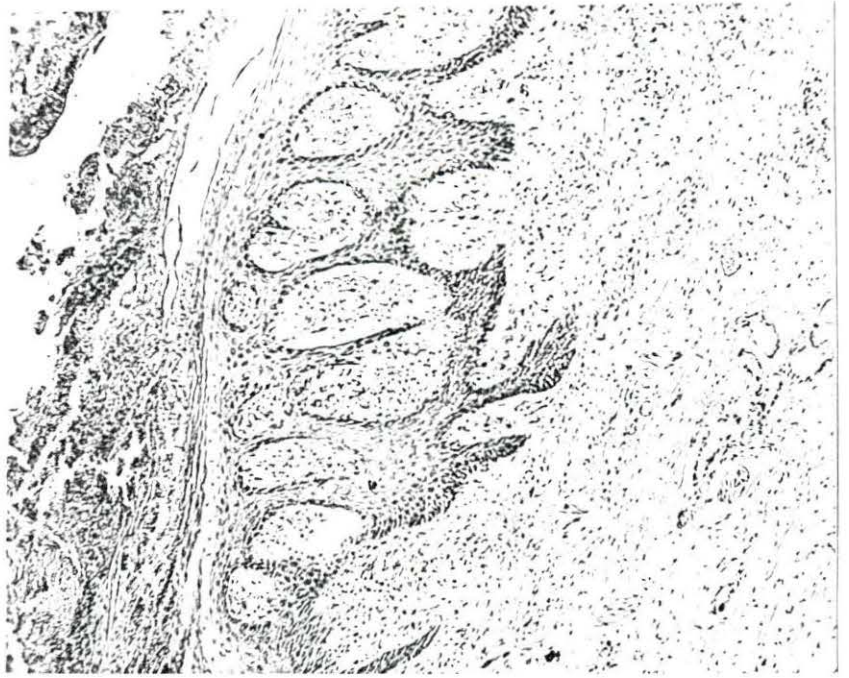




Fig. 30 The carpal glands are not spared by the dermatitis. Area 22.  
x 35.

Fig. 31 Skin from area 22 of control pig. x 35.

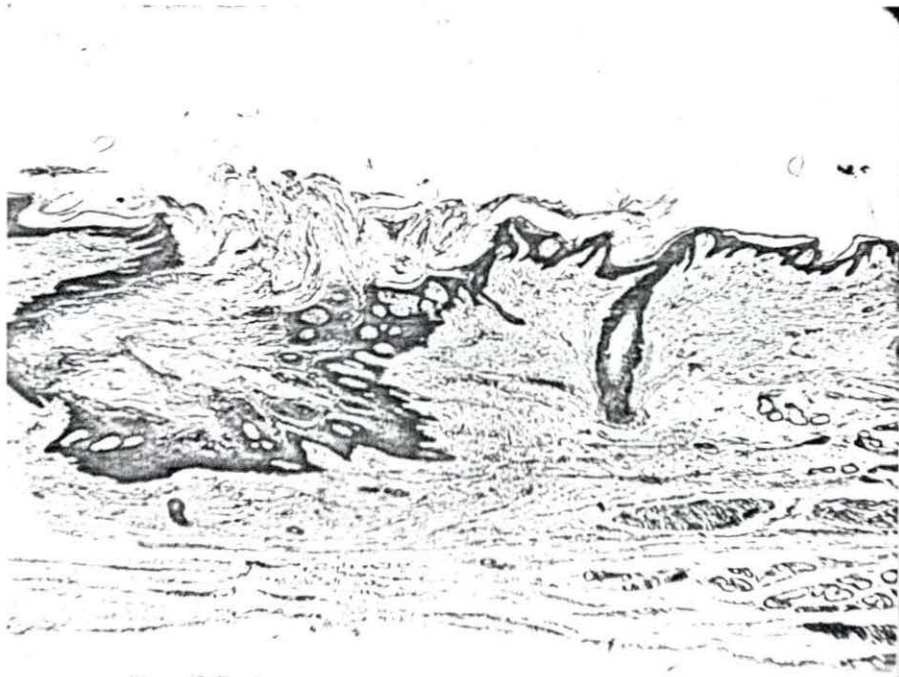
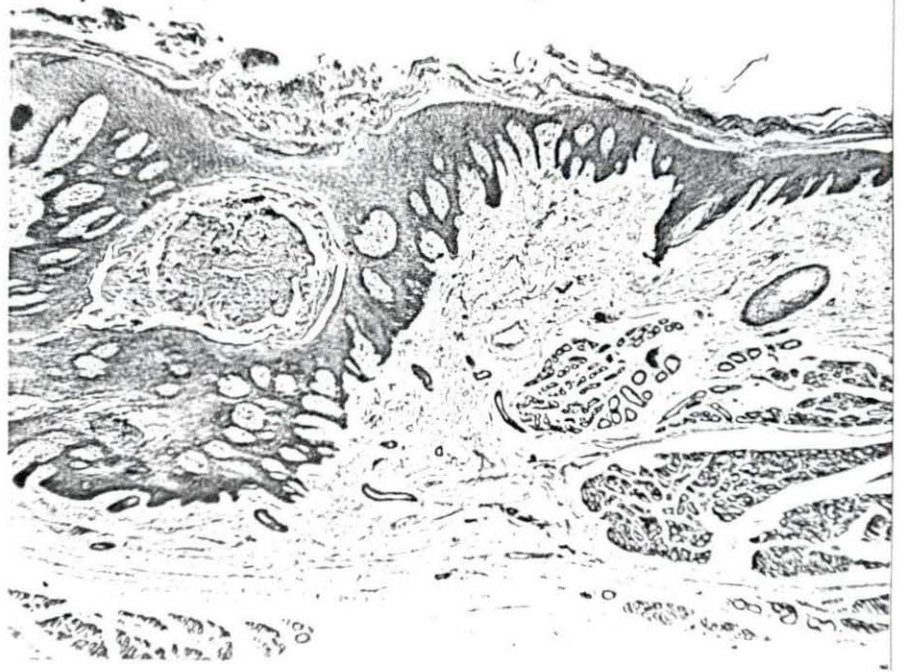

Fig. 32 The center of this photomicrograph marks a margin of a volar interungulate skin ulcer. Note the severe inflammation to the reader's left of this area marked by coagulation necrosis of the outer half of the stratum spinosum. Area 20. x 35.

Fig. 33 Skin from area 20 of control pig. x 35.






Fig. 34 Compound papillae formation and a wide fissure as seen here are two prominent lesions often observed. In the upper center of this photomicrograph is an islet of skin with marked hyperemia of the papillary dermis. Area 11. x 35.

Fig. 35 Skin from area 11 of control pig. x 35.



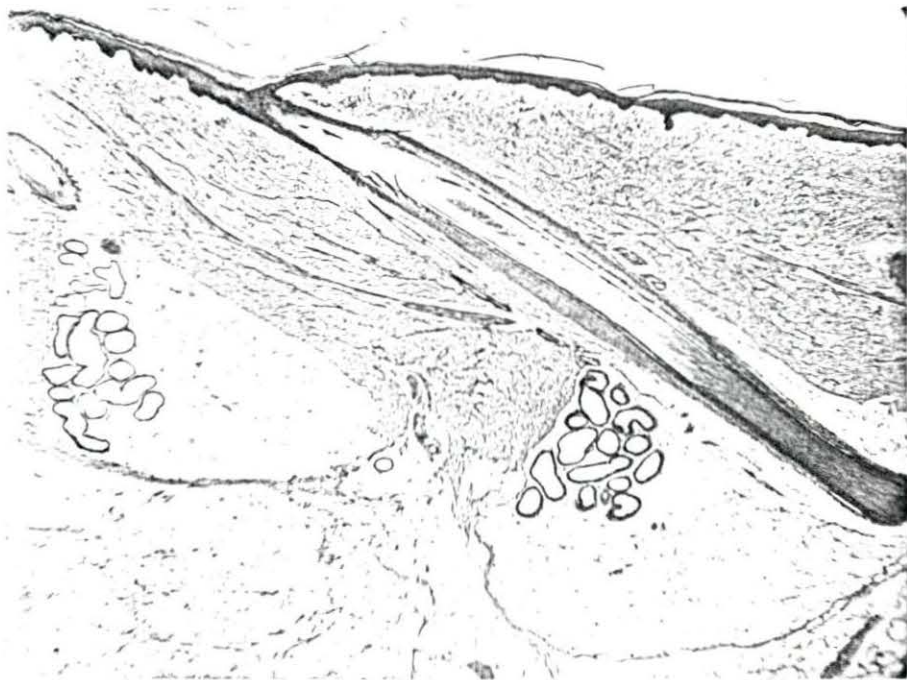
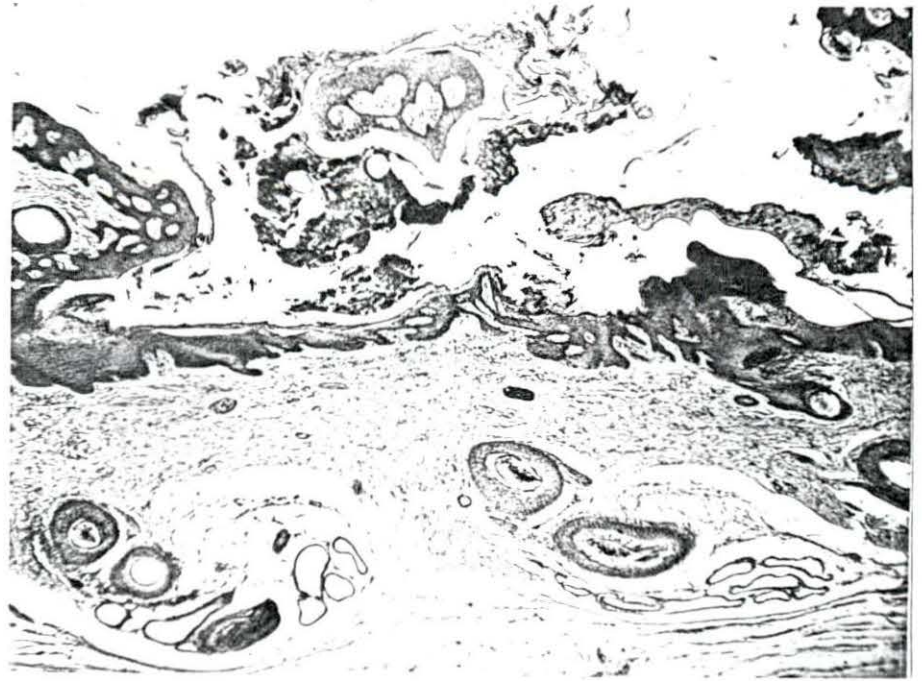


Fig. 36 Photomicrograph taken at a low magnification to show the complete involvement of the tail circumference. Area 27.  
x 11.

Fig. 37 Skin from area 27 of control pig. x 11.

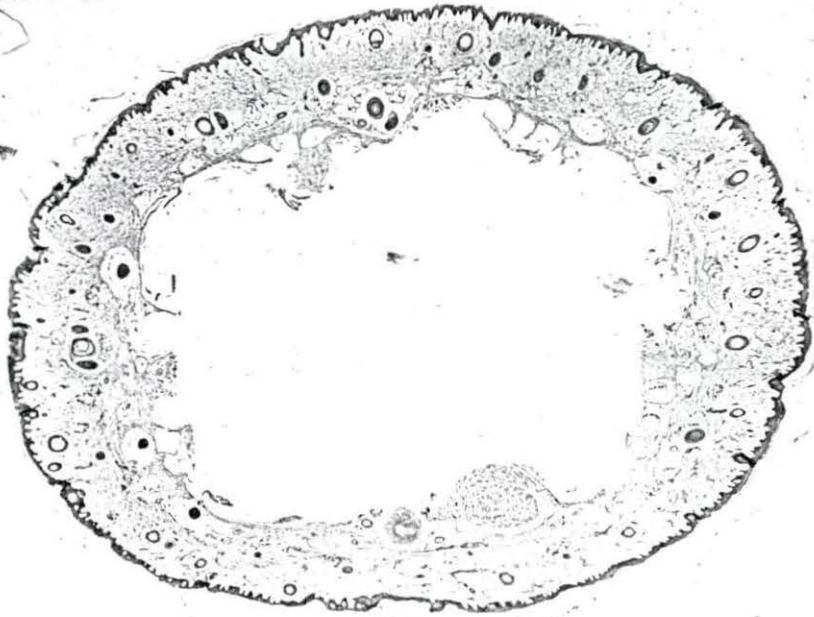
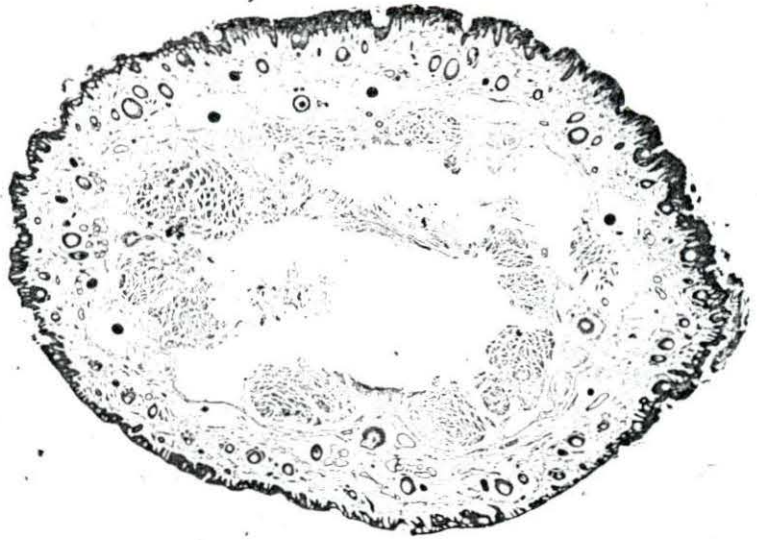


Fig. 38 A photomicrograph, at a higher magnification, of an area shown in Fig. 36 reveals the presence of both coagulation and dry necrosis of the epidermis. The dermis is also badly damaged. x 90.

Fig. 39 A photomicrograph, at a higher magnification, of an area shown in Fig. 37. x 90.



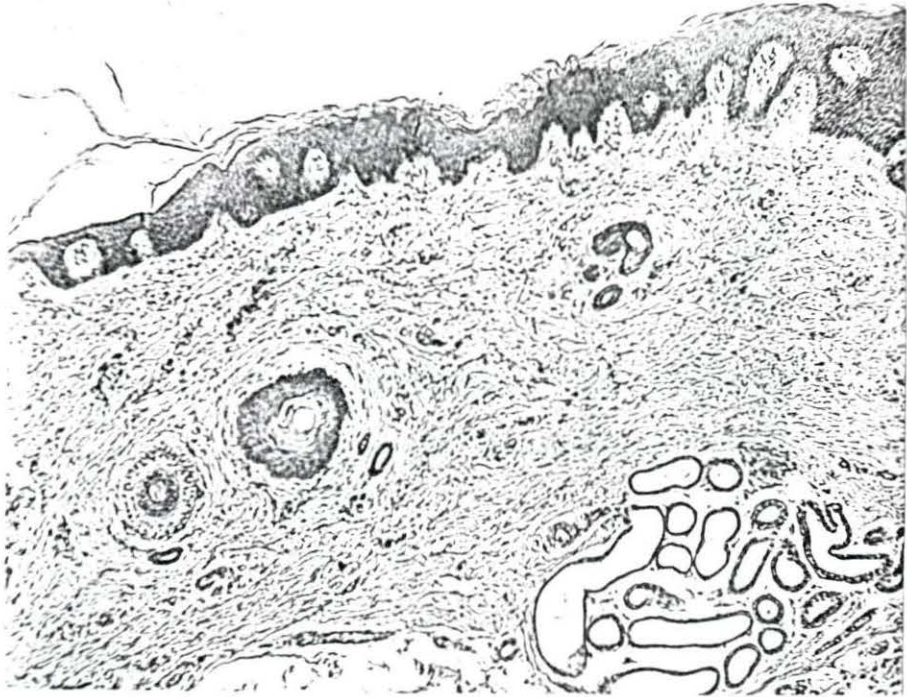
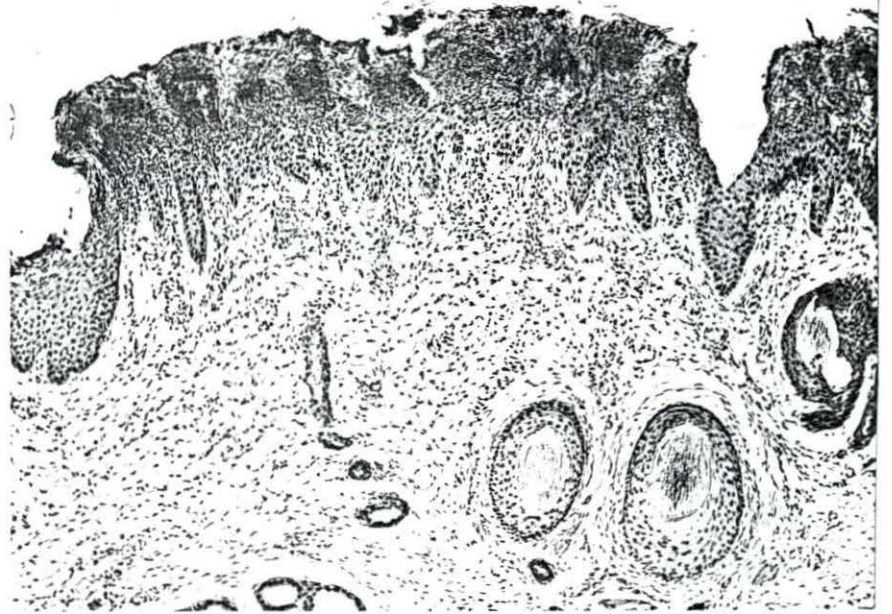
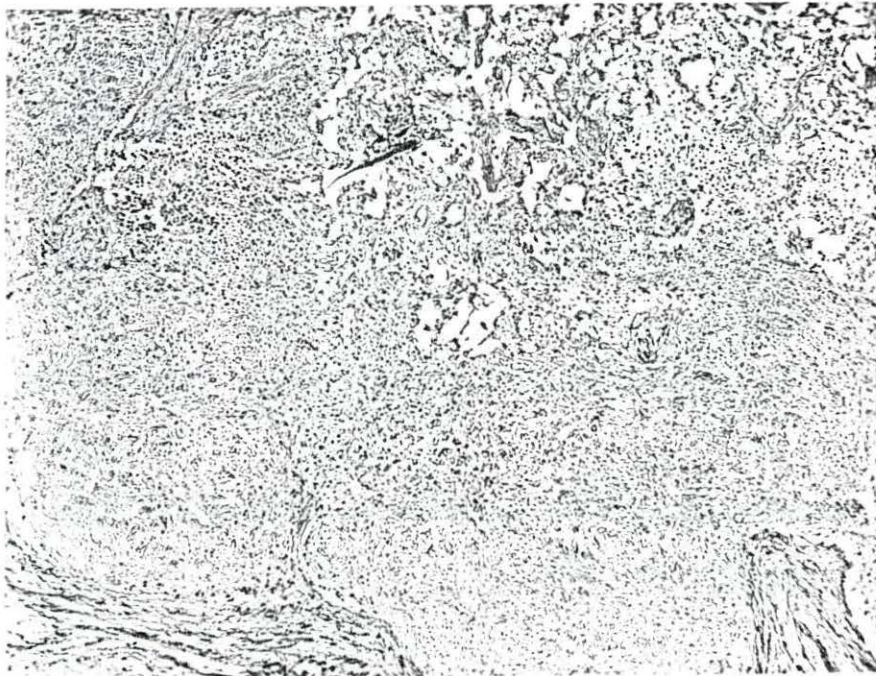
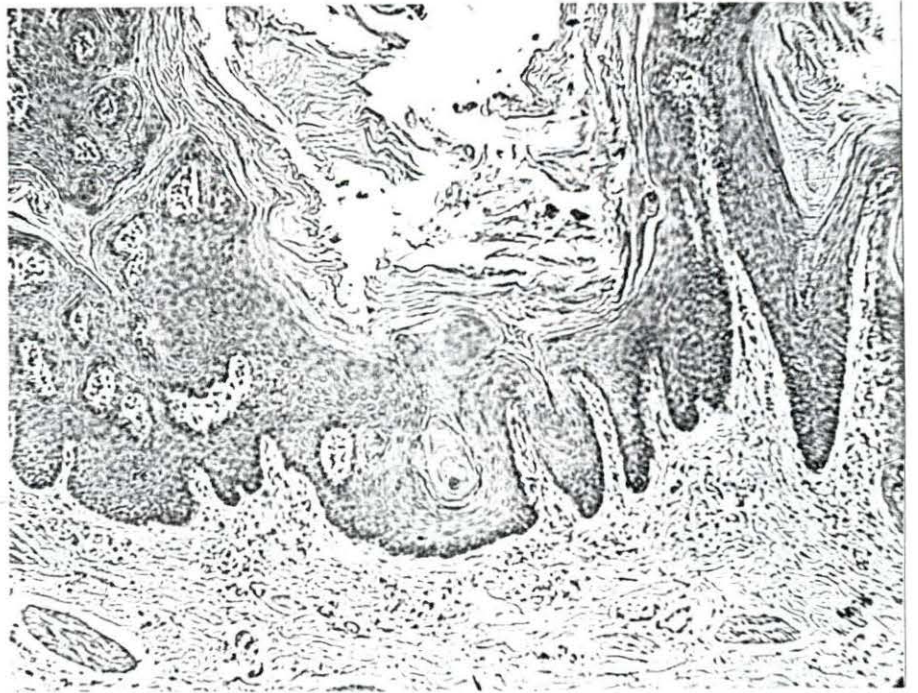

Fig. 40 Photomicrograph of a skin section removed from the specimen shown in Fig. 6. Subacute form. Area 16. x 90.

Fig. 41 This photomicrograph of a lymph node shows hyperplasia and eosinophilia. Periodic acid-Schiff stain. x 90.







#### X. ACKNOWLEDGMENTS

The writer wishes to express his sincere appreciation for the invaluable guidance and counsel of Dr. E. A. Benbrook of the Department of Veterinary Pathology, throughout the course of this investigation.

In addition, the writer is deeply grateful to Dr. P. C. Bennett, Supervisor of the Iowa Veterinary Medical Diagnostic Laboratory. It was through his cooperation and helpful interest that made it possible to obtain data and specimens, and pursue this investigation. It was solely through his efforts that the photographs of the gross specimens were obtained.

Finally, the writer wishes to acknowledge his indebtedness to the following:

Members of the Iowa Veterinary Medical Diagnostic Laboratory, the Department of Veterinary Pathology, and the Department of Veterinary Hygiene for their help given in many ways during his association with them.

Mr. Donald T. Mason for his excellent technical assistance in the handling of tissue specimens.

Mr. L. A. Facto of Iowa Agricultural Experiment Station for his fine photomicrography.

Veterinary practitioners and livestock owners in the State of Iowa who furnished data and specimens for study.

17